

中文題目：復發性舌癌合併心包膜填塞和完全房室結阻斷:一病例報告

英文題目：Recurrent Tongue Cancer Complicated with Cardiac Tamponade and

Complete AV block- A Case Report

作者：楊峰菁 黃少凡 翁國昌 蔡青峰 曾思文

服務單位：中山醫學大學附設醫院內科

Background: Tongue cancer with extension or metastasis to heart is very rare. We present a case of recurrent tongue cancer with complicated cardiac tamponade and complete AV block. A cardiac examination was performed after pericardiocentesis and thus, heart metastasis was detected.

Materials and Methods (Case Report) : A 53-year-old male, known case of squamous cell carcinoma of the tongue diagnosed at the age of 43 years for which wide excision was done. He had disease free for 9 years until it was developed local recurrent lesion. In June 2009, the patient underwent wide excision and radical neck dissection for left neck nodes. Concurrent chemoradiotherapy and radiotherapy were given. In May 2010, he was admitted with severe dyspnea. At our emergent department, physical examination showed jugular vein distention, distant heart sound and hypotension. An electrocardiogram revealed complete AV block (Figure 1). Because cardiac tamponade was highly suspected, we performed pericardiocentesis and some bloody fluid was drawled out. Temporal transvenous pacemaker was also inserted for symptomatic heart block. Occasionally, echocardiography revealed tumor masses occupying the RA and RV cavity (Figure 2). However persisting complete AV block was found, permanent pacemaker was implanted. We also performed pericardiotomy for refractory pericardial effusion. Unfortunately, the patient was dead of heart failure one month later.

Conclusion: In general, the physical examination of cardiac tamponade is Beck's triad (distant heart sound, increasing jugular venous pressure, hypotenstion), reflex tachycardia and pulsus paradoxus. However our patient's electrocardiogram revealed complete AV block (Figure 1), it's not compatible with cardiac tamponade. If one cancer patient presents pericardial effusion with or without tamponade, atrial arrhythmia and heart block, heart metastasis should be considered.

Reference:

Reynen K, *et al.* Frequency of primary tumors of the heart. *Am J Cardiol.* 1996;77(1):107.

Lam KY, Dickens P, *et al.* Tumors of the heart. A 20-year experience with a review of 12,485 consecutive autopsies. *Arch Pathol Lab Med.* 1993;117(10):1027.

Giovanna Masci, *et al.* Metastasis of Hepatocellular Carcinoma to the Heart: A Case Report and Review of the Literature. *Tumori*, 90: 345-347, 2004

FIGURE 1

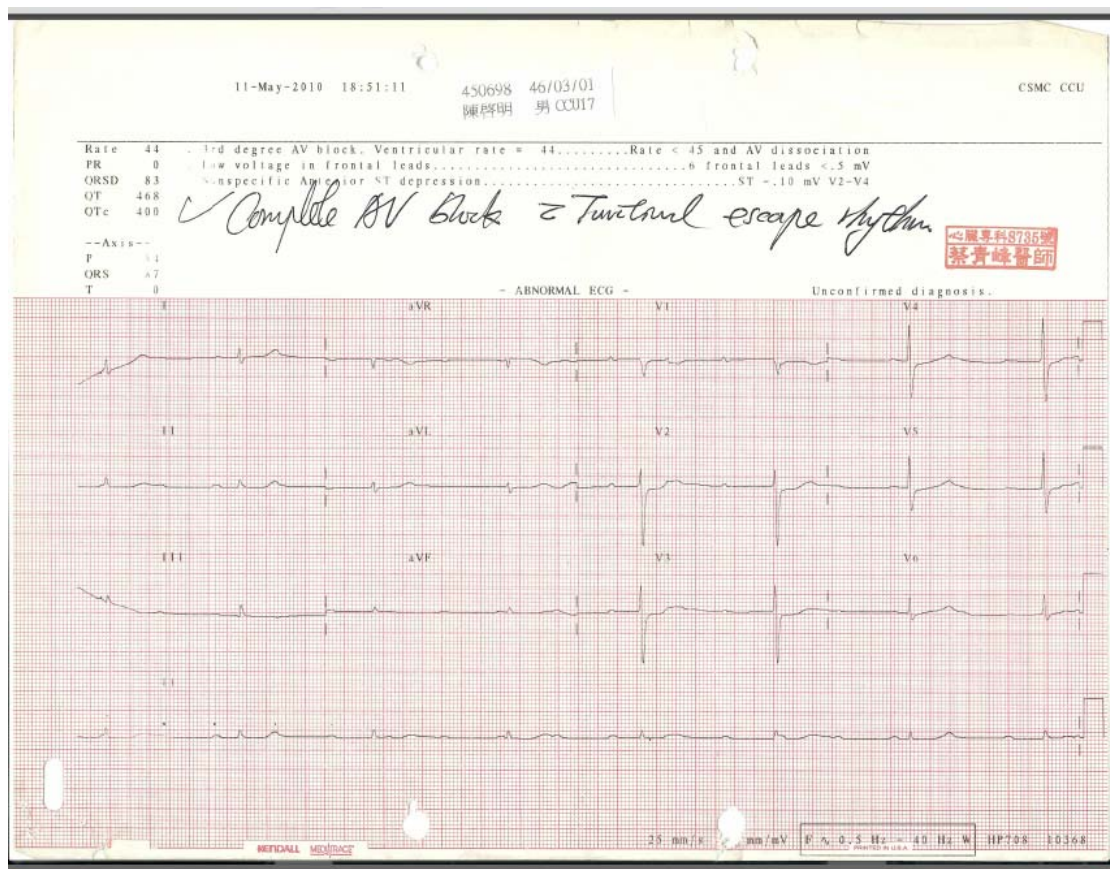


FIGURE 2

