

中文題目：在一個洗腎的多囊腎患者發現多顆腎臟腫瘤，診斷是.....?

英文題目：Multiple renal tumors in a dialysis patient with polycystic kidney, what is the diagnosis?

作者：王舜禾¹ 王韋智¹ 洪惠萱² 夏清智² 徐永勳²

服務單位：台北市立聯合醫院仁愛院區內科¹；腎臟科²

The prevalence of renal cell carcinoma (RCC) was higher in patients with autosomal dominant polycystic kidney disease (ADPKD) and end stage renal disease (ESRD), with >1 year on dialysis, it would be 2 to 3 times more frequent than RCC in patients with ESRD alone. Also, acquired cystic disease in dialysis patients is associated with a 4 to 7% incidence of renal cell carcinoma after initiating dialysis for 7~10 years. Here, we report a patient with polycystic kidney and ESRD under hemodialysis who was found to have multiple renal tumors.

A 52-year-old female patient was transferred to our hospital for long-term hemodialysis. She had been diagnosed to have ADPKD for more than 25 years. She developed gross hematuria with bilateral flank pain 3 years after starting hemodialysis.

The renal echo arranged revealed bilateral multiple cysts with multiple hyperechoic mass lesions. Those renal masses were identified with fat density under CT scan. Urine cytology examinations were negative for malignant cells.

RCC has been reported in patient with ADPKD, and RCC can also develop in patients under hemodialysis. However, when we arrange a renal biopsy for the renal masses, the result was angiomyolipoma !!

To the best of our knowledge, combination of ADPKD and renal angiomyolipoma had never been reported in the literature. Is the patient a world first reported case? or we have to consider the diagnosis more thoroughly ?

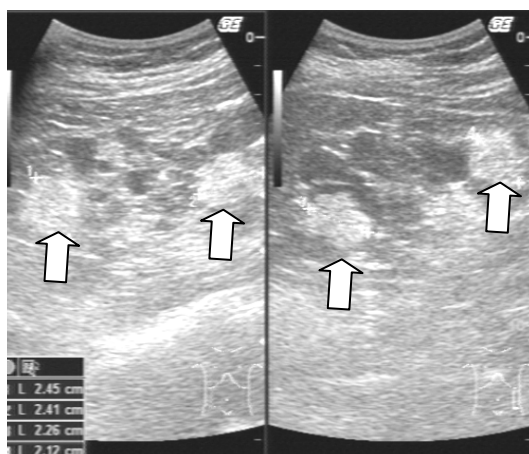


Figure: Renal echo showed multiple masses (arrows) over bilateral cystic kidney

關鍵字：體染色體顯性多囊性腎臟病,多囊腎,腎血管肌肉脂肪瘤,

Keywords: ADPKD, Polycystic kidney, Renal angiomyolipoma