

中文題目：肝硬化併巨大陰囊水腫出血：病例報告

英文題目：A bleeding giant abdominoscrotal hydrocele

作者：陳立祥¹、李青長¹

服務單位：國軍高雄總醫院 內科部¹

Case Presentation: A 43-year-old male with alcoholic cirrhosis presented with a 6-month history of progressive abdominal distension and swelling of the left scrotum. Physical examination revealed a transilluminated, nontender, 23 × 27-cm abdominoscrotal hydrocele (ASH). Intermittent bleeding from the scrotum was noted on post-admission day 11 (Figure 1A). We consulted a genitourinary surgeon and initiated local treatment involving the placement of simple interrupted sutures (Figure 1B). Abdominal computed tomography revealed massive ascites in the peritoneal cavity, communicating with the left scrotum, which contributed to the ASH (Figure 2A and B). We applied epinephrine solution, silver sulfa cream on sterile gauze pads (12.5 cm × 20 cm), and an elastic gauze bandage over the bleeding sites, which successfully controlled the bleeding. Because of the presence of massive ascites due to liver cirrhosis, we administered diuretics (furosemide and spironolactone) and albumin, transfused fresh frozen plasma, and performed repeated abdominal paracentesis. After 4 weeks of aggressive treatment, the volume of the hydrocele finally decreased (Figure 3A and B).

Discussion: The ASH in the present case was hourglass shaped and filled with abdominal components communicating with the scrotum through the inguinal canal.¹ The pathogenesis of ASH in most cases is characterized by the abnormal secretion of fluid from the tunica vaginalis, which causes progressively increasing pressure within the scrotum. Fluid is transmitted through the internal inguinal ring to the abdominal cavity, resulting in expansion superiorly, in accordance with Laplace's law.^{1,2,3} In this case, the volume of ascites flowing from the abdominal cavity to the scrotum increased the pressure within the scrotum. Spontaneous bleeding may have resulted from the injury to the superficial scrotal capillaries due to the unbearably high pressure within the scrotum. The possibility of scrotal bleeding due to other causes such as angiokeratoma,⁴ hemocele, and varicocele formation were excluded. In most cases, surgical treatment of the ASH is recommended. However, surgery was contraindicated in our case due to coagulopathy caused by the liver cirrhosis. Thus, only local treatment with sutures to control the bleeding was performed.

References

1. Blackwell RH, Kouri A, Ellimoottil C, Bresler L, Turk TM. Massive abdominoscrotal hydrocele. *Curr Urol* 2013;2:110-2
2. Pankaj Kumar Garg, Dharmendra Prasad, Vivek Agrawal, Suchi Bhatt, Debajyoti Mohanty, Indubhushan Dubey. Abdominoscrotal hydrocele: an insight into its origin. *Hernia* 2011;15:587–589
3. José Luis Cuervo, Héctor Ibarra, Mariana Molina. Abdominoscrotal hydrocele: its particular characteristics. *Journal of Pediatric Surgery* 2009;44:1766–1770
4. Trickett R, Dowd H. Angiokeratoma of the scrotum: a case of scrotal bleeding. *Emerg Med J* 2006;10:e57

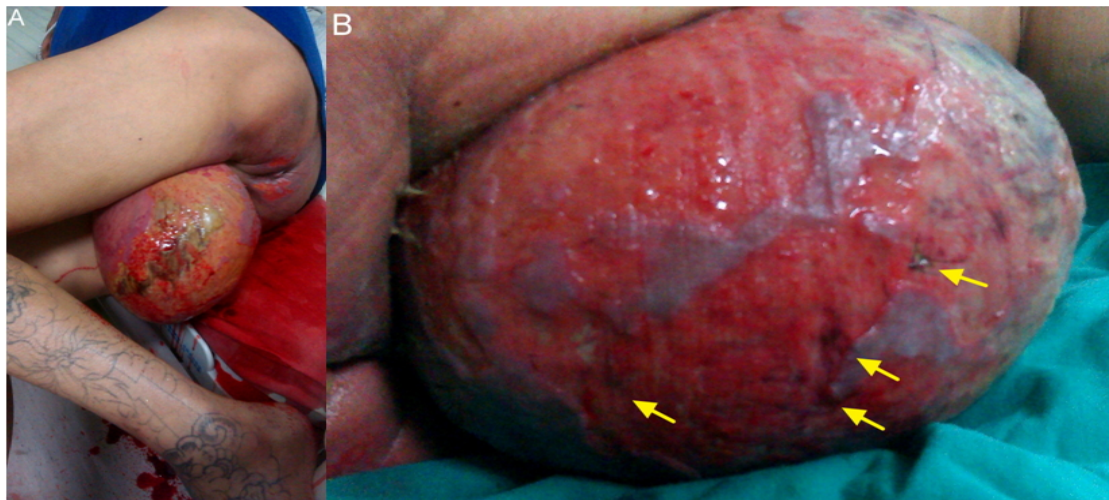


Figure 1

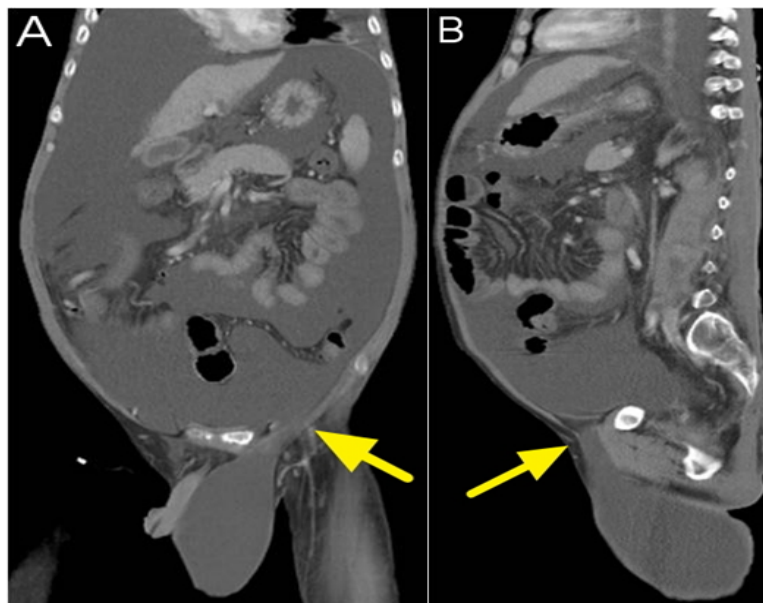


Figure 2

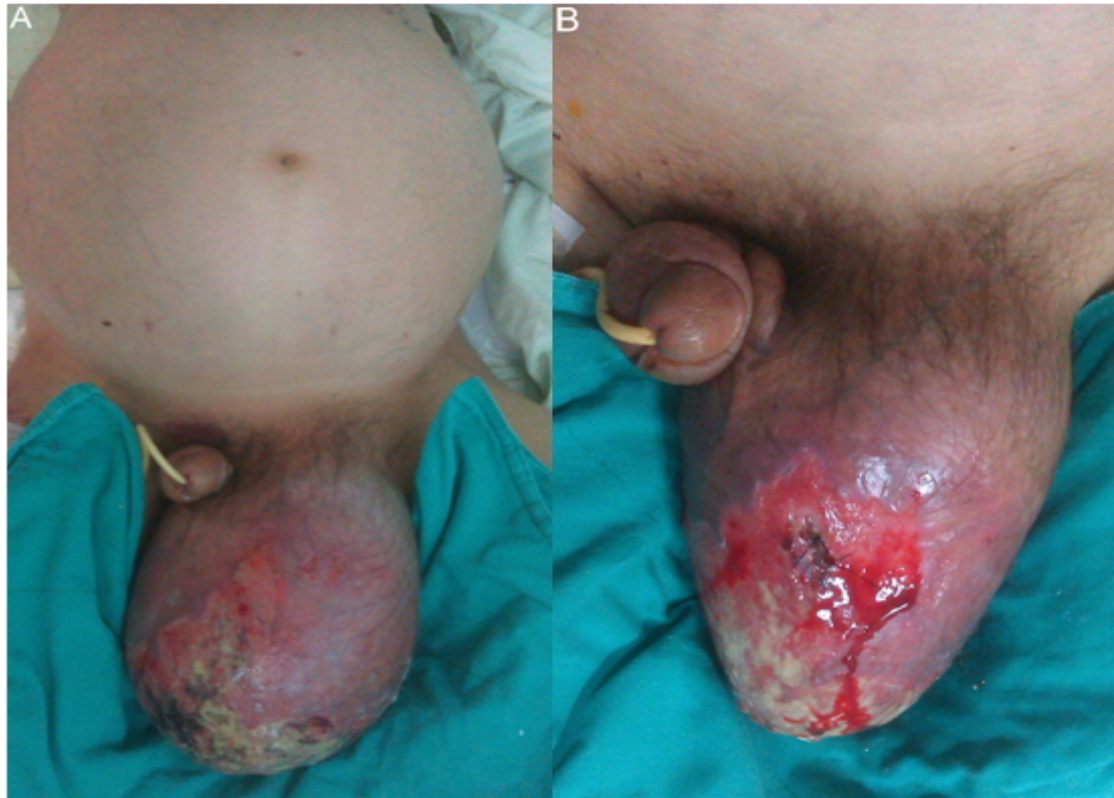


Figure 3