

中文題目：氣管神經鞘瘤合併呼吸窘迫經軟式支氣管鏡支架置入術急救及外科手術切除治療

英文題目：Tracheal schwannoma with respiratory distress rescued by flexible bronchoscopic stent implantation and cured by surgical resection

作者：游千瑩^{1,2}，吳秉儒^{1,2}，廖偉志^{1,2}，陳家弘^{1,2}，涂智彥^{1,2}

服務單位：¹中國醫藥大學附設醫院內科部；²中國醫藥大學附設醫院胸腔內科

Case Report :

The 68-year-old male smoker with the history of hypertension, type 2 diabetes mellitus, and hyperthyroidism post radioactive iodine therapy presented at chest outpatient department (OPD) because of progressive shortness of breath for 4 months.

Four months ago, his shortness of breath developed and cough with whitish sputum was accompanied. Dyspnea on exertion was also mentioned. There was no fever, chest pain, dysphagia, body weight loss, or night sweating. He visited local hospital where asthma was impressed initially because physical examination revealed high pitch breath in both inspiratory and expiratory phases. Medications for asthma control were prescribed, but his symptoms didn't got improving.

At our OPD, physical examination showed bilateral clear breath sounds with focal stridor over neck. Chest radiograph revealed nodular lesion over upper trachea (Figure 1). Because of severe dyspnea, bronchoscopy was performed and a firm tracheal tumor was found in upper trachea and the lumen near total occlusion was noted. Emergent flexible bronchoscopic tumor biopsy and stent implantation (Figure 2, 3) were performed to rescue his dyspnea. But, initial pathology report of bronchoscopic biopsy revealed favor fibrous lesion.

After a series survey of tracheal tumor, we arranged tumor resection with laryngopharyngectomy, esophagectomy, resection of upper posterior part of trachea and flap reconstruction. The immunohistochemistry study of tumor cells are diffuse positive for S100, CD34 and negative for CK, desmin and smooth muscle actin, compatible with immunoprofile of schwannoma. The patient was relatively stable after 3-month follow-up.

Discussion:

Primary tracheal tumor is one of the rare malignancies in the upper airway which accounts only 2%. Tracheal tumors usually present the symptoms with sore throat, hemoptysis, dry cough, chest pain, and dyspnea. Due to the very low incidence and

the difficulties in diagnosis via chest radiograph, the tracheal tumor patients are often misdiagnosed. Primary neurogenic tumours of the trachea as schwannomas or neurilemmomas are extremely uncommon.

Airway stent placement for malignant airway stenosis relieves symptoms immediately and improves quality of life. In this case, we performed the flexible bronchoscopy to tracheal stent implantation and patient's dyspnea got improved after the procedure immediately. Although the tracheal stent can't treat the tracheal malignant tumor, it is a useful method to rescue the fatal respiratory symptoms.

Conclusion:

Tracheal tumor is rare and tracheal schwannoma is very rare. It is easily misdiagnosis because of the non-specific respiratory symptoms. We should take more attention in unexplained respiratory symptoms. Tracheal stent may relieve respiratory distress immediately in well-selected tracheal narrowing patient.

Figure 1.

Chest radiograph revealed occupied lesion (arrow) in upper trachea.

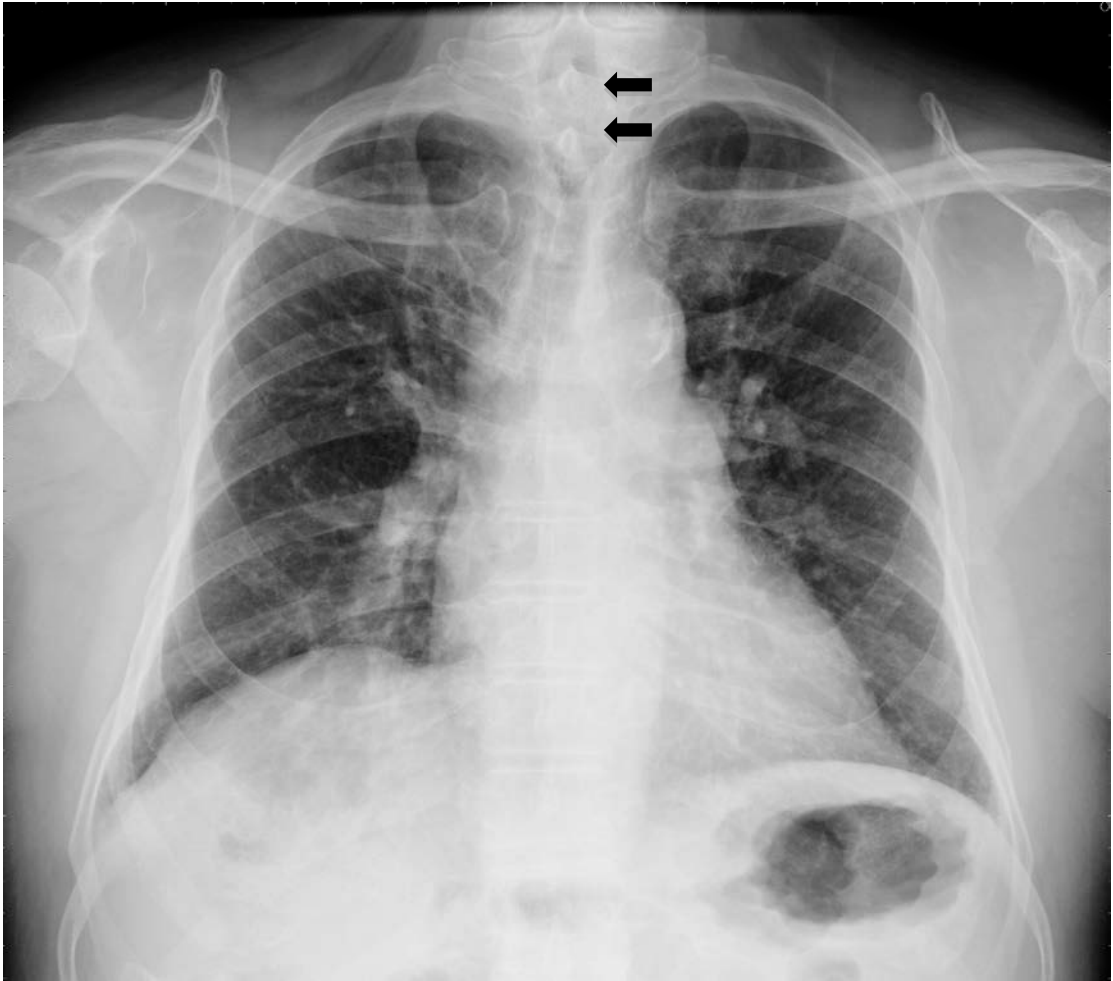


Figure 2

Bronchoscopy revealed a mass lesion in trachea and the tracheal lumen with near total occlusion was found.

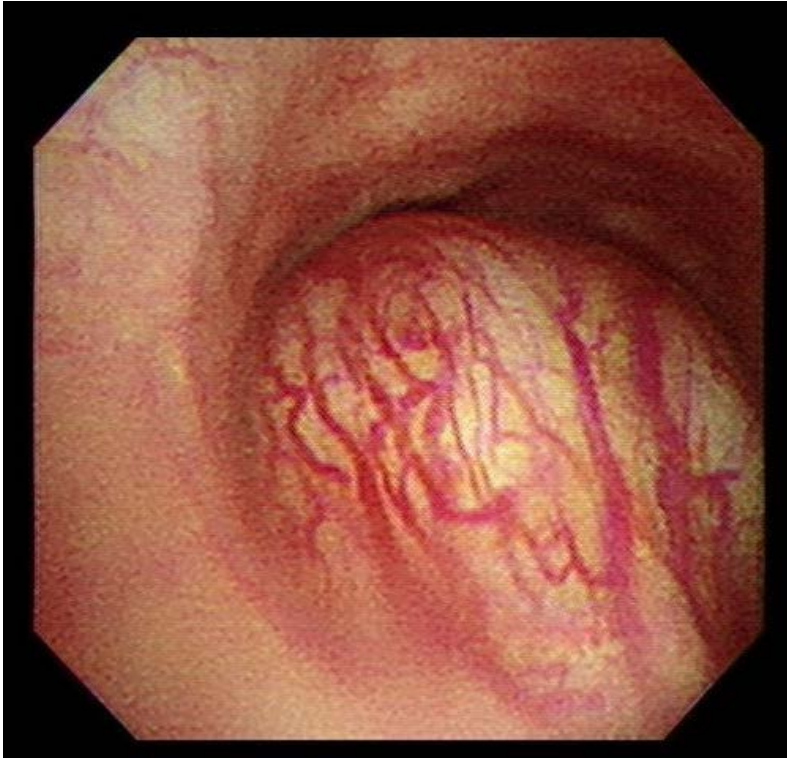


Figure 3

After flexible bronchoscopic stent implantation, the tracheal lumen recovered.

