

中文題目：Ceftriaxone 引發之假性膽囊結石把急性腎盂腎炎治療變複雜

英文題目：Ceftriaxone-associated Biliary Pseudolithiasis Complicates The Treatment of Acute Pyelonephritis

作者：蔡宗育¹，張永裕^{1,2,3} 李智雄^{1,2,3}

服務單位：¹高雄醫學大學附設中和紀念醫院一般科；²高雄醫學大學附設中和紀念醫院一般醫學內科；³高雄醫學大學附設中和紀念醫院內科部

Background

Ceftriaxone is a safe and widely used third-generation cephalosporin due to its convenience of administering once or twice daily. However, complications of biliary pseudolithiasis and nephrolithiasis have been reported. Despite its high incidence (10.1%-46.5%), patients are usually asymptomatic (0-19%), making diagnosis extremely difficult. Fortunately, pseudolithiasis is usually reversible, resolving spontaneously after the cessation of antibiotic treatment. Nevertheless, doctors should be aware of this condition. We present a case of biliary pseudolithiasis after intravenous ceftriaxone therapy.

Clinical case

A 34-year-old Vietnamese female masseur presented at our emergency department due to persistent fever and chillness, general malaise and right flank pain for 2 days. She denied of abdominal discomfort in recent years after her caesarean section, or other medical diseases, such as diabetes mellitus, hypertension, chronic renal failure or hepatitis.

On examination, her body temperature was 38.1°C, with blood pressure of 118/84mmHg, heart rate 113 beats per minute, and respiratory rate 16 breaths per minute. Blood tests revealed leukocytosis with neutrophil predominance and elevated C-reactive protein level of 130.81mg/L. Abnormal liver function tests (SGOT 68 IU/L, SGPT 54 IU/L) were observed. Urinalysis revealed hematuria (OB 2+, RBC 11-25 /HPF) and pyuria (WBC 3+, sediment WBC 26-50/HPF). Under the suspicion of acute pyelonephritis, ceftriaxone 2 gm was administered intravenously twice daily. As fever and severe chillness persisted, intravenous gentamycin 120 mg was added on the second day of hospitalization. On the third day, the patient remained febrile with severe intermittent right flank pain and nausea/emesis. Emergent non-enhanced abdominal CT revealed right nephritis and stool impaction in the descending and sigmoid colon, but without any remarkable findings in her bowel, gall bladder, biliary tracts or liver parenchyma.

Gentamycin was discontinued as fever subsided the next day, but the patient continued to have poor oral intake and lay on her left side due to right flank discomfort and general malaise. On the fifth day, one episode of spiking fever with the complaint of epigastralgia and right upper quadrant abdominal discomfort was observed. After prescribing regular strocain three times a day, her epigastralgia improved.

Under antibiotics treatment, costovertebral pain progressively subsided. Strangely, intermittent right upper quadrant discomfort persisted. On the eighth day after ceftriaxone therapy, abdominal echo revealed a gallbladder stone, which was not detected in previous abdominal CT study. Ceftriaxone-associated biliary pseudolithiasis was suspected (figure 2). Due to improved clinical condition and laboratory data (CRP 134.75 \rightarrow 12.78 mg/L), the patient requested to be discharged without further evaluation and therapy. Thus, we advised conservative treatment and arranged outpatient department follow-up with echo study for the resolution of the gallbladder pseudolithiasis.

Discussion

Ceftriaxone is eliminated from the body via urine (40 to 60%) or bile (11 to 65%). In bile, its concentration can reach 20 to 150 times of serum concentration. In animal study, Arpacik et al reported that ceftriaxone could inhibit gallbladder contractility. These may predispose to the formation of ceftriaxone-calcium complex and biliary sludge, which can be detected on CT images as high-density signal because of the calcium precipitate. Increasing risk of side-effect of ceftriaxone are found in children administered with ceftriaxone dosage of ≥ 60 mg/kg/day, patients with renal disease, patients who are fasting, dehydrated, receiving total parenteral nutrition or remain bedridden. Therefore, oral intakes, early ambulation and hydration should be encouraged in patients receiving ceftriaxone therapy to avoid the development of biliary pseudolithiasis.

Newly developed gallbladder stone may be accompanied with new fever episode, sudden onset biliary colic and epigastralgia. Although pseudolithiasis usually disappears spontaneously, biliary sludge as well as associated cholecystitis, cholangitis, and pancreatitis should be monitored with echo study in order to avoid unnecessary medical expenses and surgical interventions that can compromise the patient's health.

References

1. Richards D.M., Heel R.C., Brogden R.N., Speight T.M., Ceftriaxone Avery G.S. A review of its antibacterial activity, pharmacological properties and therapeutic use. *Drugs*. 1984;27:469–527.
2. Schiffman M.L., Keith F.B., Moore E.W. Pathogenesis of ceftriaxone – associated biliary sludge. In vitro studies of calcium-ceftriaxone binding and solubility. *Gastroenterology*. 1990;99:1772–1778.
3. Cohen D., Appel G.B., Scully B., Neu H.C. Pharmacokinetics of ceftriaxone in patients with renal failure and those undergoing hemodialysis. *Antimicrob Agents Chemother*. 1983;24:529–532.
4. Biner B., Oner N., Celtik C., Bostancioğlu M., Tunçbilek N., Güzel A., et al. Ceftriaxone-associated biliary pseudolithiasis in children. *J Clin Ultrasound*, 34 (2006), pp. 217-222
5. Murata S., Aomatsu T., Yoden A., Tamai H. Fasting and bed rest, even for a relatively short period, are risk factors for ceftriaxone-associated pseudolithiasis. *Pediatr Int*. 2015;57:942–946.
6. Park HZ, Lee SP, Schy AL. Ceftriaxone-associated gallbladder sludge. Identification of calcium-ceftriaxone salt as a major component of gallbladder precipitate. *Gastroenterology*1991;100:1665-70.
7. Arpacik M, Ceran C, Kaya T, et al. Effects of ceftriaxone sodium on in vitro gallbladder contractility in guinea pigs. *J Surg Res*. 2004;122(2):157–61.

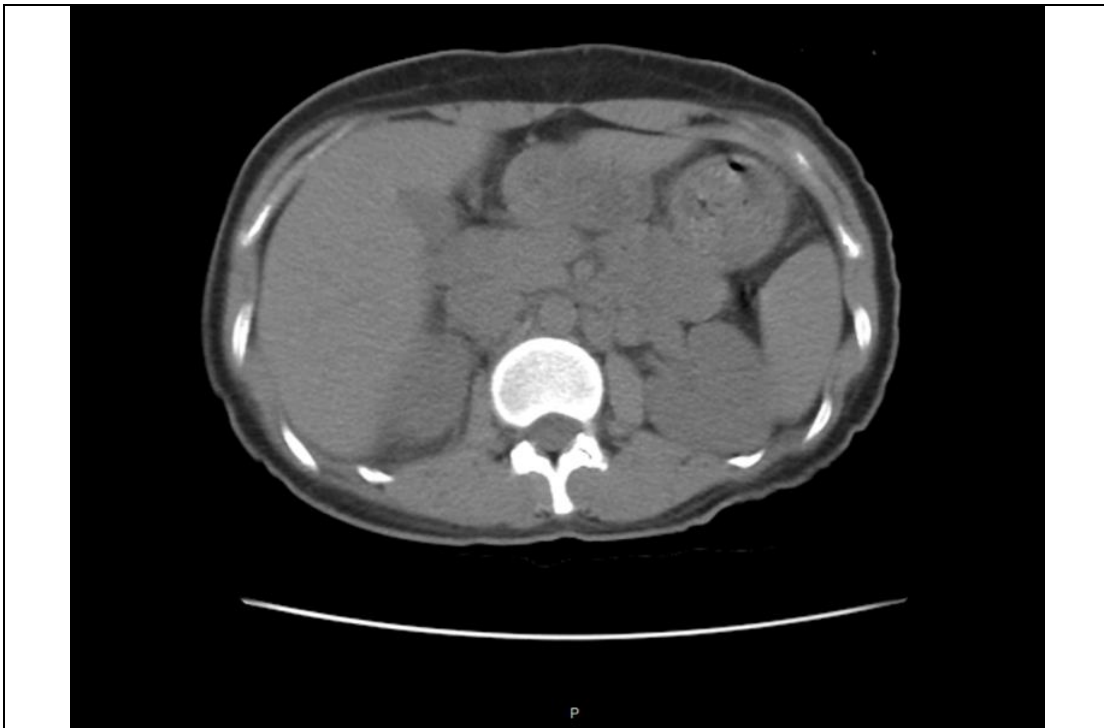

Figure 1. Abdominal CT prior to ceftriaxone treatment showing unremarkable gallbladder and bile ducts

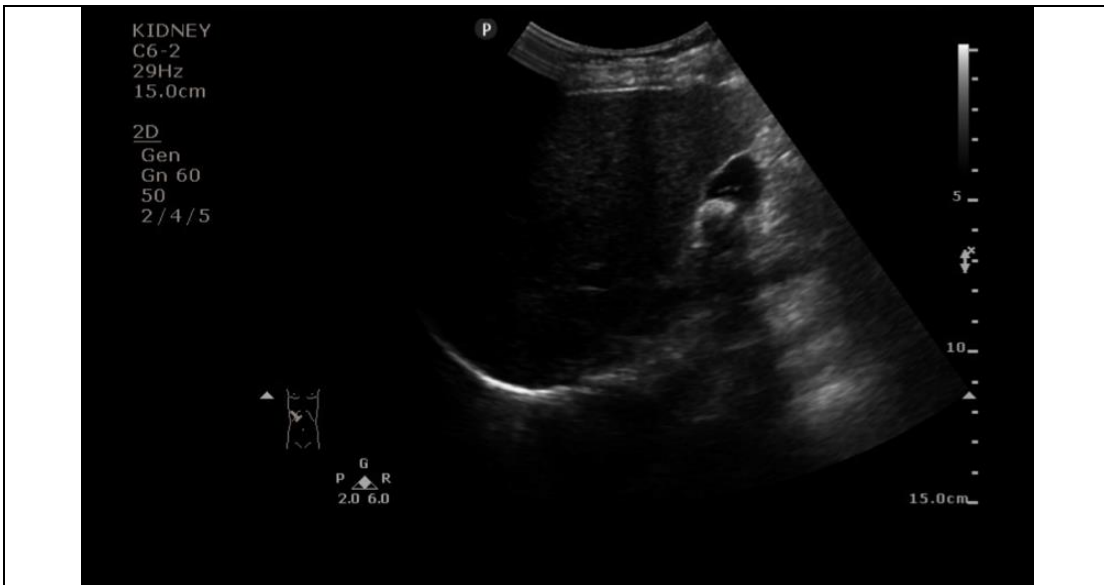


Figure 2. Abdominal echo finding of a biliary pseudolithiasis after one week of ceftriaxone treatment