

中文題目：轉移性胸腺瘤患者肺外結核合併諾卡菌病綜合症病例報告及文獻探討

英文題目：Disseminated Nocardiosis Coinfection with Extrapulmonary Tuberculosis in a Patient with Metastatic Thymoma: A Case Report and Literature Review

作者：李卓豪<sup>1</sup>，王永志<sup>2</sup>，黃子權<sup>1</sup>，何景良<sup>1</sup>，葉人華<sup>1\*</sup>

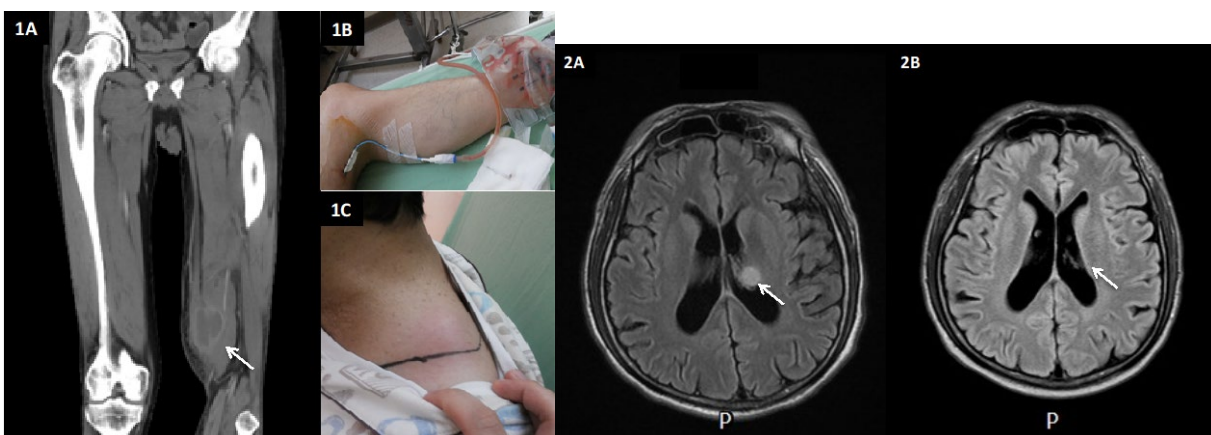
服務單位：<sup>1</sup>三軍總醫院血液腫瘤科；<sup>2</sup>三軍總醫院感染科

Conflict of interest：None of the authors has any potential financial conflicts of interest

Running Title: Nocardiosis coinfection with extrapulmonary TB in a metastatic thymoma patient

### Abstract

*Metastatic thymoma post-intensive chemotherapy and radiotherapy is prone to get opportunistic infectious diseases. Disseminated nocardiosis is a rare disease; however, its incidence has increased in recent years due to the growing population of immunocompromized hosts. We present the first report on *N. beijingensis* infection with coinfection of extrapulmonary tuberculosis, causing muscular and brain abscess in a patient with metastatic thymoma post intensive chemotherapy and radiotherapy. This case illustrates the possibility of co-infection with two pathogens and the difficulty of establishing a rapid diagnosis. Awareness of the opportunistic infection and early initiation of appropriate antibiotic therapy are important for the treatment of immunocompromized patients with infectious diseases.*



<i>Table 1</i> Author/Year	Region	Patient	Year Gender	Symptoms	Predisposing factor	Infection sites	Treatment regimen	Outcome
Kageyama et al 2004 (11)	Thailand and Japan	NA	70y/M	NA	NA	Pulmonary nocardiosis	TMP/SMX, MEPM and levofloxacin	Recovery
Chu et al 2008 (12)	China	Systemic Lupus Erythematosus	13y/F	Fever, Dyspnea	High-dose PSL, MMF	Pulmonary nocardiosiswith massive lung abscess	IV MEPM for 4 weeks, shifted to oral TMP/SMX for 1 year	Recovery
Takayanagi et al 2008 (13)	Japan	Interstitial pneumonia	60y/F	Dry Cough	NA	Pulmonary nocardiosis	TMP/SMX, MEPM and levofloxacin	Died
Ohmori et al 2011 (14)	Japan	Prostate cancer with multiple bone metastases	79y/M	Refractory skin eruption on left forearm	C/T with docetaxel, PSL	Cutaneous nocardiosis, left forearm	Oral garenoxacin 400 mg/day for 2 weeks.	Recovery
Martinaud et al 2011 (15)	France	Human immunodeficie ncy virus infection	47y/M	BW loss (5 kg)	HIV (47,833 copies/ml), CD4 39/mm <sup>3</sup> )	Pulmonary nocardiosis with abscess	IMP and AMKI for 3 weeks, shift to oral TMP/SMX for 3 months	Recovery

Ogawa et al. 2011 (16)	Japan	Living kidney transplant	48y/M	Cough, Fever	MMF, FK506	PSL,	Pulmonary nocardiosis	IV IMPM 0.5 g/Q12H for 30days, shifted to ceftriaxone 2 g/QD for 12 days, shifted to oral Minocycline for 3months	Recovery
Derancourt et al 2012 (17)	France	Immunocompetent	42y/F	Small, crusted ulcerations, painless skin lesion	NA		Cutaneous nocardiosis, lower left leg	Oral TMP/SMX Q4H for 2 months	Recovery
Arunachalam et al 2014 (18)	Italy	Renal transplant	47y/M	scratched by a bush. Red slightly painful lesion of right thigh	cyclosporine, MMF, PSL		Cutaneous nocardiosis, right thigh	Oral Ciprofloxacin, garenoxacin (400 mg/day) for 3 weeks	Recovery
Aragaki-Nakahodo et al 2014 (19)	USA	Kidney and pancreas transplant	50y/F	Dry cough	MMF, FK506	PSL,	Pulmonary nocardiosis	High dose oral TMP/SMX for 6 months	Recovery

Crozier et al 2014 (20)	USA	Immunocompetent	48y/M	Dry cough, Fever, Drenching night sweats, BW loss	NA		Pulmonary nocardiosis	IV ceftriaxone for 6 weeks, shifted to oral TMP/SMX for 6 months	Recovery
Rigotti et al 2015 (21)	Italy	Immunocompetent	75y/M	Fever, Abdominal pain, Constipation, Low back pain	NA		Isolated lumbar nocardiosis	subfascial spine IMP and AMKI for 2 weeks, shifted to oral TMP/SMX for 3 weeks	Recovery
Palavutitotai et al 2015 (22)	Thailand	Cadaveric renal transplant	58y/M	Fever, Fatigue, BW loss(7 kg), Left groin pain	MMF, FK506	PSL,	Psoas muscle abscess	Percutaneous drainage and IV TMP/SMX and IMP for 2 weeks, shifted to IV TMP/SMX for 4 weeks, shifted to oral TMP/SMX for 4 weeks.	Recovery
Abdel-Rahman et al 2015 (23)	Israel	Immunocompetent (breast cancer s/p OP)	55y/F	Fever,cough, Hemoptysis, BW loss(5kg)	NA		Endobronchial pulmonary nocardiosis	IV ceftriaxone for 1month, shift to oral TMP-SMX for 3 months	Recovery

Richards et al 2015 (24)	Australian	Syphilis, HBV, metastases	Bony	80y/M	Arthralgia, Fever, Headaches, Visual hallucinations, Deteriorating left vision	NA	Disseminated nocardiosis subretinal and cerebral abscesses)	(Bilateral abscesses AMKI	IV MEPEM for 1 week and shifted to	Recovery
Sheikh-Taha et al 2017 (25)	USA	Multiple sclerosis		50y/F	Cough, Dyspnea, Fever, loss(5kg)	BW Alemtuzumab (12 mg/m <sup>2</sup> )	Pulmonary with sepsis	nocardiosis	IV MEPM for 4 weeks	1g/q8h Recovery

---