

## **Clinical Features of Human Intestinal Capillariasis in Tai-tung**

**Ming-Jong Bair, Tsang-En Wang\*, Tai-Cherng Liou\*, Shee-Chan Lin\*,  
Chin-Roa Kao\*, Tao-Yeuan Wang\*\*, and Kwok-Kuen Pang\*\*\***

**Department of Gastroenterology, \*\*\*Department of Radiology, Mackay  
Memorial Hospital, Taitung Branch, Taitung; and \*Department of  
Gastroenterology,  
\*\*Department of Pathology, Mackay Memorial Hospital, Taipei**

### **Abstract**

Human intestinal capillariasis is a rare parasitosis that was first recognized in the Philippines in the 1960s. The parasitosis is a life threatening disease and has been reported from Thailand, Japan, South of Taiwan (Kaoh-Siung), Korea, Iran, Egypt, Italy and Spain. Clinical symptoms are characterized by chronic diarrhea, abdominal pain, borborygmi, marked weight loss, protein and electrolyte loss and cachexia. Capillariasis may be fatal if treatment is not given early. We reported 7 cases living in rural areas of Taiwan. They had no history of travelling abroad. Two cases had the diet of raw freshwater fish before. Two cases received emergency laparotomy due to peritonitis and found of enteritis cystica profunda. According to the route of transmission, freshwater and brackish-water fish may act as the intermediate host of the parasite. The most simple and convenient method of diagnosing capillariasis is stool examination. Two cases were diagnosed by histology. Mebendazole or albendazole 200mg orally twice a day for 20-30 days as the treatment of choice. All the patients were cured, and relapses were not observed within 12 months. ( J Intern Med Taiwan 2001;12:303-308 )

**Key Words :** Human infection, Capillaria Philippinensis, Intestinal capillariasis

### **Introduction**

Capillaria species parasitize many classes of vertebrates, although only 4 species described have been found in humans: Capillaria Phillipinensis, Capillaria plica, Capillaria aerophila, and Capillaria hepatica 1. C. Phillipinensis is a tiny nematode that was first described in the 1960s as the causative agent of severe diarrheal syndromes in humans. In 1962, the first case of human intestinal capillariasis occurred in a previously healthy young man from Luzon

( Philippines ) who subsequently died. At autopsy, a large number of worms, later described as *C. Philippinensis*, were found in the large and small intestine 2. The disease was first reported by Chitwood et al in 1964 3. During the Philippine epidemic from 1967-1968, more than 1300 persons acquired the illness and 90 patients, with parasitologically confirmed infections died 4. In late 1978 and early 1979, another small outbreak was identified in northeastern Mindanao, the Philippines, and about 50 persons acquired the infection 4. Sporadic cases continued to appear in northern Luzon as well as in other areas where epidemics have occurred. The disease is also endemic to Thailand, and was first reported in 1973 5. Sporadic cases have also been found in Iran 6, Egypt 7,8, Taiwan 9, Japan 10,11, Indonesia 12, Korea 13, Spain ( probably acquired in Colombia ) 14 and Italy ( acquired in Indonesia ) 15, indicates that this infection is widespread. Because the infection results in a severe disease with a high mortality when untreated, early diagnosis is very important. Here we describe 7 cases of human intestinal capillariasis found in Tai-tung since 1991 till 2001.

#### Materials and Methods

Since 1991, 7 cases diagnosed as intestinal capillariasis in Tai-tung, all with the symptoms of chronic diarrhea, abdominal pain, borborygmi and marked weight loss, all patients were hospitalized for examination and treatment. Diagnosis was confirmed by eggs and/or larvae and/or adult *C. Philippinensis* found in the feces of 5 patients. Two cases were re-recognized by a pathologist by histology of jejunum or ileum ( Figure 1 , 2 ) due to no finding in the stool examination. Bacterial cultures of stool specimens showed negative findings in all patients. The stool specimens were examined by way of formalin-ether concentration method. *C. Philippinensis* eggs are peanut-shaped with flattened bipolar plugs, 20×40 µm in size ( Figure 3 ).

#### Results

Seven cases, five male and two female, were 39 to 69 years of age when they were diagnosed as intestinal capillariasis ( Table 1 , 2 ). All of them lived in Taitung County. Five of them were aborigines. All of them have no history of travelling abroad. Two patients had the history of eating raw or insufficiently cooked fresh-water fish. Three of 7 patients had a mixed infection with *Clonorchis sinensis* or *Strongyloides stercoralis* which eggs were also observed in the feces. Two cases received emergency laparotomy due to peritonitis and pathology revealed jejunitis cystica profunda. Small bowel series and colonoscopic study revealed mild dilatation and thickened mucosa of jejunum and ileum ( Figure 4 ), which suggested malabsorption. Laboratory findings revealed anemia, malabsorption of fats and sugars

and low levels of potassium, sodium, calcium and total protein in serum. Mebendazole 200 mg twice a day for 20 days was given to 7 patients. All of them were cured and relapses were not observed within 12 months following chemotherapy and supportive treatment.

## Discussion

Parasitic infection with *C. philippinensis* should be considered as one of the etiologies in patients with malabsorption syndrome 16. The delay in diagnosis was commonly seen for more than 4 months and, in some cases, even years in this study due to Taiwan not being an endemic area of *C. philippinensis* infection 17.

Capillariasis are closely related to *Trichuris* and *Trichinella* species 1. The eggs of *Trichuris trichiura* and *C. philippinensis* are similar although differentiable 18, and some individuals can be infected with both parasites. In fact, 10 of the 11 patients described by Whaler et al. 19 were infected both *T. trichiura* and *C. philippinensis*. An inexperienced observer may confuse the eggs of *Capillaria* with those of *T. trichiura* 1, although a correct parasitological diagnosis is easily made by finding characteristic peanut-shaped eggs with flattened bipolar plugs 2.

The origin of *C. philippinensis* for the 7 patients who have no history of going abroad is unknown. In Thailand and the Philippines, infection had been attributed to eating raw or insufficiently cooked fish harboring larvae 2,20. Hakkaueses in Taiwan like to eat raw, freshwater fish. They might have shown a high prevalence rate of *C. philippinensis* infection if the fish in Taiwan should have been infected. All 7 cases lived in the eastern parts of Taiwan, closest to Luzon, in the Philippines. Imported fish from the Philippines are highly suspected as the source of infection. Fish bought from the markets of Tai-tung County, Taiwan, have been examined for *C. philippinensis* infection, but the result was negative. Recent findings suggest that fishing-eating birds may be the natural definitive hosts 21. These birds such as *Bulbulcus ibis*, *Nycticorax nycticorax*, and *Ixobrychus sinensis* are found in Taiwan 22. Therefore, the possibility of man acquiring the infection by directly or indirectly eating fresh-water fish with a larval stage of the parasite in this island cannot be neglected.

Enteritis cystica profunda is a mucin-filled cystic space, lined by non-neoplastic columnar epithelium, in the wall of small intestine, predominantly the submucosa, histology simulate mucinous carcinoma 23, they may occur in esophagus 24, and the stomach 25,26. The irregular distribution of the glands and cysts with normal-appearing glandular epithelium containing mucus and Paneth's cells are features suggestive of its benign nature 27.

Albendazole is presently considered the drug of choice for the treatment of human

intestinal capillariasis because it is effective against eggs, larvae, and adult worms 1, 28. Major textbooks on infectious diseases recommended mebendazole ( 200mg orally twice a day for 20 days ) as the treatment of choice 29. Attempts to reduce the standard schedule of mebendazole ( 400mg daily for 3 weeks ) were not successful in Thailand 30. All the patients were cured, and relapses were not observed within 12 months following therapy.

Finally, according to published literatures, any cases in nonendemic areas with symptoms of chronic diarrhea, borborygmi, abdominal pain, and marked weight loss, should be viewed as intestinal capillariasis. The conditions of the modern world are favorable to spreading the infectious disease rapidly because of improvements in international travel.

#### Reference

1. Cross JH. Intestinal capillariasis. Clin Microbiol Rev 1992;5:120-9.
2. Cross JH. Intestinal capillariasis. Parasitol Today 1990;6:26-8.
3. Chitwood MB, Valasquez C, Salazar NG. Capillaria philippinensis sp. N. (Nematoda: Trichinellida) from the intestine of man in the Philippines. J Parasitol 1968;54:368- 71.
4. Cross JH, Singson CN, Battad S, Basaca-Sevilla V. Intestinal capillariasis:epidemiology, parasitology and treatment. Proc R Soc Med Int Cong Symp Ser 1979; 24:81-6.
5. Pradatsundarasar A, Pecharanond K, Chintanawongs C, Ungthavorn P. The first case of intestinal capillariasis in Thailand. Southeast Asian J Trop Med Pub Hlth 1973;4:131-4.
6. Hoghooghi-Rad N, Maraghi S, Narenj-Zadeh A. Capillaria philippinensis infection in Khoozestan Province, Iran: case report. Am J Trop Med Hyg 1987;37:135-6.
7. Youssef FG, Mikhail EM, Mansour NS. Intestinal capillariasis in Egypt: a case report. Am J Trop Med Hyg 1989;40:195-6.
8. Mansour NS, Anis MH, Mikhail EM. Human intestinal capillariasis in Egypt. Trans R Soc Trop Med Hyg 1990;84:114.
9. Chen CY, Hsieh WC, Lin JT, Liu MC. Intestinal capillariasis: report of a case. J Formos Med Assoc 1989;88:617-20.
10. Mukai T, Shimizu S, Yamamoto M, et al. A case of intestinal capillariasis. Jpn Arch Int Med 1983;3-:163-9.
11. Nawa Y, Imai JI, Abe T, Kisanuki H, Tsuda K. A case report of intestinal capillariasis. The second case found in Japan. Jpn J Parasitol 1988;37:113-8.
12. Chichino G, Bernuzzi AM, Bruno A, et al. Intestinal capillariasis (Capillaria philippinensis) acquired in Indonesia: a case report. Am J Trop Med Hyg

1992;47:10-2.

13.Lee SH, Hong ST, Chai JY, et al. A case of intestinal capillariasis in the Republic of Korea. *Am J Trop Med Hyg* 1993;48:542-6.

14.Dronda F, Chaves F, Sanz A, Lopez-Velez R. Human intestinal capillariasis in an area of nonendemicity: case report and review. *Clin Infect Dis* 1993;17:909-12.

15.Chichino G, Bernuzzi AM, Bruno A, et al. Intestinal capillariasis (*Capillaria philippinensis*) acquired in Indonesia: a case report. *Am J Trop Med Hyg* 1992;47:10-2.

16.Paulino GB, Wittenberg J. Intestinal capillariasis: a new cause of a malabsorption pattern. *Am J Roentgenol Radiother Nucl Med* 1973;117:340-5.

17.Hwang KP. Human intestinal capillariasis in Taiwan. *Acta Paed Sin* 1998;39:82-5.

18.Zaman V, Keong LA. Helminths in: *Handbook of Medical Parasitology*. 2nd ed. Edinburgh: Churchill Livingstone, 1990;87-217.

19.Whalen GE, Rosenberg EB, Strickland GT, et al. Intestinal capillariasis: a new disease in man. *Lancet* 1969;1:13-6.

20.Bhahulaya M, Indra-Ngarm S, Anathapruit M. Freshwater fishes of Thailand as experimental intermediate host for *Capillaria philippinensis*. *Int J Parasitol* 1979;9:105-8.

21.Bhahulaya M, Indra-Ngarm S. *Amauornis phoenicurus* and *ardeola bacchus* as experimental definite hosts for *capillaria philippinensis* in Thailand. *Int J Parasitol* 1979;9:321-2.

22.Cross JH, Basaca-Sevilla V. Experimental transmission of *capillaria philippinensis* to girds. *Trans R Soc Trop Med Hyg* 1983;77:511-4.

23.Kyriakos M, Condon SC. Enteritis cystic profunda. *Am J Clin Pathol* 1978;69:77-85.

24.Volrol MW, Welsh RA, Genet EF. Esophagitis cystica. *Am J Gastroenterol* 1973;59:446-53.

25.Oberman HA, Lodmell JG, Sower ND. Diffuse heterotopic cystic malformation of the stomach. *N Engl J Med* 1963;269:909-11.

26.Fonde EC, Rodning CB. Gastritis cystica profunda. *Am J Gastroenterol* 1986;81:459- 64.

27.Andersib NJ, Rivera ES, Flores DJ. Peutz-Jeghers syndrome with cervical adenocarcinoma and enteritis cystica profunda. *West J Med* 1984;141:242-4.

28.Cross JH, Basaca-Sevilla V. Albendazole in the treatment of intestinal capillariasis. *Southeast Asian J Trop Med Public Health* 1987;18:507-10.

29.Nash TE. Visceral larva migrans and other unusual helminth infections. In: Mandell GL, Douglas RG Jr, Bennett JE, eds. *Principles and Practice of Infectious Diseases*. 3rd ed. New York: Churchill Livingstone, 1990:2157-61.

30.Basaca-Sevilla V, Cross JH. Attempts to modify treatment of intestinal capillariasis. Southeast Asian J Trop Med Public Health 1985;16:546-8.

**Table 1.**  
**Characteristics of seven patients with Intestinal Capillariasis Reported in Taitung.**

Case No.	Year Occurred	Occupation	Age	Sex	Travel history	Associated parasite	Treatment	Outcome
1	1991	Farmer	62	M	-	Clonorchis sinensis	Mebenzole	Cure
2	1991	Housewife	46	F	-	-	Mebenzole	Cure
3	1995	Farmer	61	M	-	-	Mebenzole	Cure
4	1995	Housewife	45	F	-	Strongyloides stercoralis	Mebenzole	Cure
5	1999	Farmer	39	M	-	-	Mebenzole	Cure
6	2000	Fisher-man	69	M	-	-	Mebenzole	Cure
7	2001	Farmer	50	M	-	Clonorchis sinensis	Mebenzole	Cure

Table 2.  
Clinical features and diagnostic method of seven patients with Intestinal Capillariasis Reported in Taitung.

Case No.	Duration of onset to diagnosis (days)	Diagnostic method	Chronic diarrhea	Abdominal pain	Abdominal borborygmi	Body weight loss	Anemia	Hypoalbuminemia
1	70	Stool ova	+	-	-	+	-	+
2	7	Stool ova	+	+	-	-	+	+
3	103	Stool ova	+	+	+	-	+	+
4	66	Stool ova	+	+	+	-	-	+
5	37	Histology	+	+	+	+	-	+
6	25	Histology	+	-	-	+	-	+
7	17	Stool ova	+	+	+	+	-	+

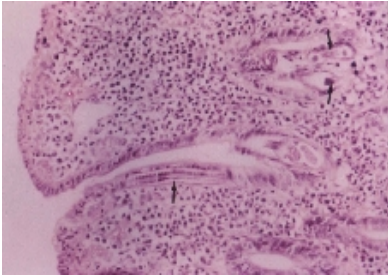


Fig.1. *C. philippinensis* worms are embedded in the intestinal mucosa (arrow). Hematoxylin and eosin, x200.

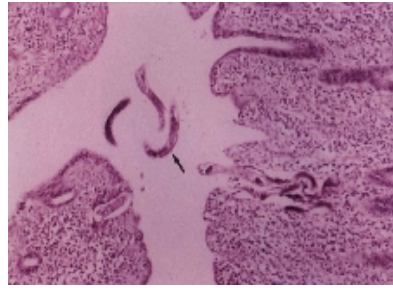


Fig.2. Multiple longitudinal sections of *C. philippinensis* are present among the mucosa surface and lumen. The longitudinal sections show a row of stichocytes (arrow). Hematoxylin and eosin, x200.

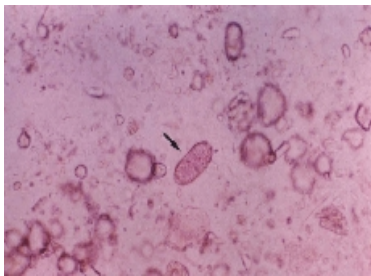


Fig.3. Egg of *C. philippinensis* in feces shows peanut-shaped with flattened bipolar plugs. x400.

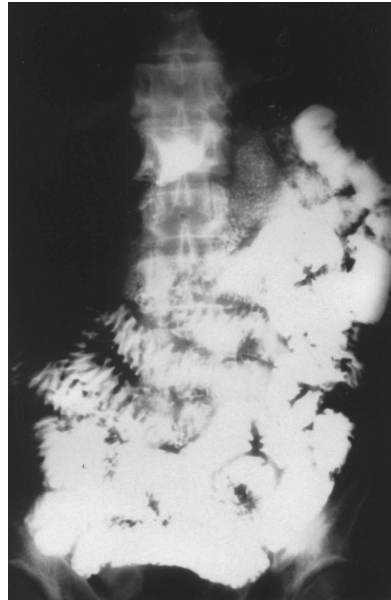


Fig.4. Forty-minute roentgenogram of small bowel series with the malabsorption pattern. Mild dilatation and thickened valvulae conniventes are shown in the jejunum and ileum.

## 台東地區菲律賓毛線蟲之臨床特徵

白明忠 王蒼恩\* 劉泰成\* 林錫泉\* 高進祿\* 王道遠\*\* 彭國權\*\*\*

馬偕紀念醫院台東分院 腸胃肝膽科 \*\*\*放射診斷科

馬偕紀念醫院 \*腸胃肝膽科 \*\*病理科

### 摘 要

菲律賓毛線蟲是一種少有的感染性疾病，首次發現是在 1960 年的菲律賓，這是一種危及生命的疾病，曾經在泰國、日本、南台灣、韓國、伊朗、埃及、義大利、西班牙發生。臨床特徵主要是腹痛、腹鳴、慢性腹瀉、體重減輕及蛋白質、電解質流失而造成惡病質。菲律賓毛線蟲感染如果不及早診斷並給予治療，仍然會有致死的可能。我們報告 7 個在台東發生的菲律賓毛線蟲感染之病例，所有病例都無出國經驗，兩個病例曾經食用淡水魚生魚片，兩個病例因腹膜炎緊急開刀發現小腸的 *cystica profunda*。感染的途徑來自食用被感染之淡水魚，最簡單方便的診斷方法是在糞便中發現蟲卵。Mebendazole 或 albendazole 200mg，一天兩次，服用 20-30 天，是有效的治療，7 位病人都完全治癒，追蹤了 12 個月，並無復發之病例發生。