

## Gastrointestinal Stromal Tumor : 2 Cases Report and Review

Po-Heng Chuang, Chi-Feng Cheng\*, Li-Ying Liao, Li-Sun Shi\*\*,  
Chaur-Shine Wang, and Ming-Jer Huang\*\*\*

Division of Gastroenterology and \*Oncology, Department of Internal Medicine,  
\*\*Department of Pathology, Taipei Municipal Jen-Ai Hospital  
\*\*\*Division of Oncology, Department of Internal Medicine,  
Taipei Mackay Memorial Hospital, Taipei, Taiwan

### Abstract

The term GISTs ( gastrointestinal stromal tumors) was introduced as a histogenetically neutral term referring to the main group of mesenchymal tumors of the gastrointestinal tract. Recent studies have shown that cells in GISTs express a growth factor receptor with tyrosine kinase activity termed c-kit, which is the product of the c-kit proto-oncogene. Clinically, the most specific and practicable diagnostic criterion for GISTs is the immunohistochemically determined c-kit (CD-117) positive expression<sup>1</sup>. Reclassification of GISTs by cell-surface expression of CD-117 is necessary. We report two cases of refractory GISTs which recurred after surgical intervention, after 1 and 4 years respectively. They received the therapy of STI571 ( glivec /imatinib, Novartis), a small molecule inhibitor of the kinase domain of c-kit<sup>2</sup>. Glivec has highly specific target inhibition of tyrosine kinase, with very good safety profile. Out of two patients, one has survived with good health and the other has died. We have reviewed the subject according to literature available. ( J Intern Med Taiwan 2002;13: 86-93 )

Key Words : GISTs ( gastrointestinal stromal tumors), c-kit, STI571(In the U.S.: Gleevec<sup>TM</sup> (imatinib mesylate); outside the U.S.: Glivec R (imatinib)

### Introduction

Gastrointestinal stromal tumors (GISTs) are the most common mesenchymal tumors of the gastrointestinal (GI) tract and constitute 1% to 3 % of GI malignancies. The patients with GISTs have a median age between 50 to 60 years, but they can also occur in the pediatric population<sup>3</sup>. GISTs have a wide clinical spectrum from benign, small nodules to frankly malignant tumors. Patients with GISTs usually present with nonspecific epigastric pain, GI bleeding and palpable masses. The patients who had

intestinal bleeding were the most likely to undergo a complete resection of the tumors, suggesting that bleeding might be a fortuitous event leading to an earlier diagnosis. Currently established treatment for GISTs is complete surgical resection of primary tumor and its metastases. Complete resection of all tumors is possible in 48% to 89 % patients according to aggressive principle 3,4. Adjuvant radiation and /or chemotherapy was not beneficial to the patients with GISTs. In fact, the patient receiving adjuvant therapy may have worse outcome. Contributing to the advanced immunohistochemistry, specific markers of GISTs denote another choice of therapy 5. The c-kit is known to be expressed in and to be functionally important in several types of cells such as hematopoietic stem cells. There is a close homology between the kinase domains of PDGFR and c-kit; therefore, it is speculated that STI 571 would also potentially inhibit the kinase of c-kit and GISTs progression 6. C-kit overexpression is necessary for STI 571 treatment. STI571 was well-tolerated and has few adverse effects. No long-term adverse effects data is available.

#### Case Presentation

##### Case 1 : Extragastrintestinal stromal tumor with complete remission

In April 2000, a 53-year-old single woman with a history of uterine myoma, presented with progressive abdominal discomfort and a palpable mass in the upper abdomen. The cystic tumor 17.5 x 16.5 x 6.2 cm 3 in size was removed with subtotal pancreatectomy and splenectomy. It was soft tissue in origin with intact pancreatic and splenic wall. Histological examination of the solid part of the specimens revealed poorly differentiated spindle cells and more than 25 cells per 10 high power microscopic field undergoing mitoses. It was positive immunohistochemical study for CD117 and CD34 and hence identified as a extra-gastrointestinal stromal tumor 7 (fig.1). The patient had twice negative abdominal sonography in the follow-up at two months interval. However, 6 months after the surgery she found one palpable mass on the right side of her umbilicus. She received retroperitoneal cancer debulk, right hemi-colectomy, hysterectomy, bilateral salpingo-oophorectomy, and cholecystectomy in January 17, 2001. At the end of January 2001, she was found to have progressive prevertebral residual tumor growth and a mass at labia major. She received radiation therapy to prevertebral residual tumor and perineum area, 3600 cGy in each from February 12 to March 20, 2001. But she developed multiple palpable subcutaneous nodules along the surgical suture line during the radiation therapy(fig. 2). She was referred to Ashford Cancer Centre, Australia and enrolled in the EORTC (European Organization for Research and Treatment of Cancer) phase II clinical trial of STI571. Treatment with four 100mg capsules (400mg) of STI571 twice daily was started in April 3, 2001 for 18 days and then she received the second positron emission tomography (PET) with 18 fluorodeoxyglucose scan study (18

FDG-PET) on April 26, 2001. It showed disappearance of her enlarged tumors. She suffered from nausea, vomiting, diarrhea, anorexia, sorethroat, sleepy, and facial swelling during her oral medication. She restarted taking the oral pills on May 3, 2001 and complained of facial edema and intermittent diarrhea with the dose of 300 mg twice daily. She received packed RBC transfusion on May 9, 2001 for anemia (Hb 8.3 g/dl). She is now well except mild facial swelling.

#### Case 2 : Glivec/Imatinib -resistent GIST

In March 1997, a 45-year-old female housekeeper underwent duodenal bulbular leiomyosarcoma resection, with the initial presentation of tarry stool passage for 10 days. The tumor was 7.1 x 5.3 x 4.2 cm<sup>3</sup> in size, hypercellular, composed of interlacing bundles of proliferating plump spindle cells with mild nuclear atypical and mitoses greater than 10 per 10 high power microscopic field. Mucosal ulceration but without tumor necrosis was seen. Retrospective immunohistochemical stain showed positive CD34 and CD117. She had recurrence 14 months later (fig.3). Whipple's procedure was carried out thereafter. She underwent her third and fourth surgery for bulky tumors in November 1999 and September 2000. In January 2001 she was found by abdominal sonography, to have multiple mixed echoic tumors beside the liver hilum, the largest one was 5.0 x 5.0 cm<sup>2</sup>. In March 2001 abdominal CT showed a 22 x 18 x 10 cm<sup>3</sup> lobulated heterogeneous mass with compression of hepatic hilum, bile ducts dilatation and vessels and abdominal wall invasion. The obstructive jaundice and cholangitis made her receiving supportive therapy only in the following time. She was referred to Ashford Cancer Centre, Australia and enrolled in EORTC phase II clinical trial in May, 2001 and was given STI571 100mg twice daily initially. The dose was increased to 200mg twice daily 14 days later. However, she still complained of abdominal fullness and abdominal CT study showed increased tumor size with massive ascites in July, 2001. She died 52 months after her initial diagnosis and on the 60th day after her first STI571 therapy.

#### Discussion

GISTs occur predominantly in persons over 40 years of age with an equal sex distribution 8. They are diagnosed in approximately 5000 individuals in the United States annually 9. GISTs are a group of mesenchymal neoplasms, however, they are the subject of much debate and controversy regarding their histogenesis, criteria for diagnosis, prognostic features, and nomenclature 10. Studies since 1990 have demonstrated that some tumors may have markers and features of neural or vascular endothelial differentiation; therefore, the term gastrointestinal stromal tumor has been adopted and denote tumors arising from the stroma with no definite cell line of origin and varying patterns of differentiation 11. However, some authors emphasize on the

CD117 and CD34 expression of GISTs<sup>12,13,14</sup>. The term "GIST" is now preferentially defined as c-kit ( CD117 ) positive mesenchymal spindle cell or epithelioid neoplasms primary in the GI tract, omentum, and mesentery<sup>13</sup>. GISTs are most common in the stomach (60-70%), followed by small intestine (20-25%), colon and rectum (5%), and esophagus (<5%)<sup>13</sup>. No specific symptoms and signs have been identified. The most important characteristic of stromal tumors is their indolent, slow-growing nature. The tumors are generally found deep within the stroma and the submucosa, and only about half have an intragastric component and are often detected as incidental findings during imaging studies. Patients with GISTs most often present with non-specific symptoms that include nausea, vomiting, upper abdominal pain, gastrointestinal bleeding, palpable abdominal mass, hollow organ perforation, obstructive symptoms or weight loss<sup>10</sup>. The symptoms depend on tumor size and site of presentation. Tumors smaller than 2cm are generally asymptomatic. Larger tumors may be symptomatic because of their size or their tendency to ulcerate and bleed. The intraluminal lesions are found with mucosal ulcer bleeding or incidentally without mucosal involvement. The extra-luminal lesion often presents as a big palpable mass with cystic change.

Surgery is still the mainstay treatment for GISTs either early or advanced stage. The patients with advanced GISTs which progress rapidly and result in organ destruction have dismal prognosis, even surgical intervention can resect large tumors and resolve some symptoms. Advanced gross surgical resection is presently the only means of cure for GISTs and significant expansion of the duration of disease and it may necessitate the removal of adjacent organs. There is no effective therapy for metastatic tumors that are resistant to traditional cytotoxic chemotherapy or radiotherapy, therefore a secondary surgical intervention must be performed to extend survival of the patients. After complete resection, 3 and 5 years survival rates are 54 % and 42 %, respectively, as compared with 13 % and 9 % after incomplete resection. Tumors with more than 1 mitosis per high power microscopic field and a size larger than 5 cm have an especially poor prognosis, with increased local and /or distant recurrence and decreased survival. The tumor, even benign-appearing after first surgery, could recur months to years later and ultimately proved fatal when they became unresectable. Neither radiation nor chemotherapy demonstrates any significant benefit and may be harmful due to the adverse effect of therapy<sup>3,4</sup>. STI571 is a small molecule kinase inhibitor, which has the potency of competitive inhibition of the ATP binding site and shows a high degree of specificity for Abl, PDGFR, and c-kit. This selective activity of STI 571 suggests that it has a relative narrow spectrum of anticancer activity. It has been applied for bcr-abl positive leukemia and has amazing effect<sup>15</sup>. Therefore, it was suspected STI571 would have high potency of inhibition for refractory GISTs<sup>5</sup>.

We are interested that this highly selective molecule has different therapeutic effect. Most malignant GISTs have mutant c-kit and series studies indicate that c-kit may be activated by mutation in at least three domains : extracellular, juxtamembrane and kinase portion (exon 9 or 11 or 13) 16,17. Multidrug resistance, resistance to numerous structurally unrelated natural product drugs such as the widely applied anthracyclines, has been associated with the overexpression of proteins, like the MDR1 gene product P-glycoprotein (P-gp) and the multidrug resistance protein-1 (MRP1) in drug-resistant cell lines and neoplastic tissue. It was suggested high P-gp and MRP1 expression in c-kit positive tumors indeed have a higher degree of drug resistance 18,19.

STI571 was generally well tolerated. The adverse effects of STI571, including nausea, vomiting, change of taste, diarrhea, skin rash, myalgia, arthralgia, periorbital edema, conjunctivitis, bleeding sclera, neutropenia and anemia, were related with the dose 9,20. However, intratumoral bleeding and even with perforation to the peritoneal cavity could happen 20. Patients receiving higher dose are more likely to have more severe adverse effect. Grade 3 and 4 toxicity occurred less than 10 % in higher dose of STI 571 treatment. STI 571 has the potency to inhibit the signal transduction via c-kit and it is predictable that it would inhibit hematopoietic stem cell resulting in neutropenia, anemia, and thrombocytopenia. Elevation of liver enzymes levels was reported and the abnormalities were reversed during treatment. Most of these side effects will be noted at about two weeks after the initiation of treatment. Blood transfusion can significantly improve the reduction of hemoglobin level and other adverse effects can be resolved by adequate medication. Even though, non-specific side effect, such as nausea and anorexia cannot be neglected as it may affect the nutrition status of the patient. Moreover, long term data for side effects is still awaiting.

#### Conclusion

With the identification of c-kit expression in GIST, the confused GIST classification could be clarified to myogenic tumors, neurogenic tumors, c-kit mutation (-) GISTs and c-kit mutation (+) GISTs 21, or even defined to be the c-kit positive mesenchymal spindle cell or epithelioid neoplasms primary in the GI tract, omentum, and mesentery 13. Aggressive surgery for complete resection of gross tumor is still the mainstay of therapy. C-kit overexpression is necessary for STI 571 treatment, but it is not ensured that all c-kit overexpressed GISTs response to STI 571 therapy. Patients with strong c-kit positive refractory malignancies could try higher dose STI571 therapy under monitoring the dose-related toxicity. Long-term side effects should be observed. We are not clear as to what is the right timing to start the STI 571 therapy. However STI571 provides us with the new concept of target-specific anti-cancer therapy rather

than blind resection of the tumor and adjacent organs. In the future, cancer chemotherapy will base on tumor typing or oncogene presentation and not on organ.

#### Acknowledgements

Special thanks to Dr. Dusan Kotasek, the Ashford Cancer Centre in Adelaide, South Australia for his help in enrolling these two patients in EORTC phase II trial.

#### References

1. Miettinen M, Sarlomo-Rikala M, Lasota J. Gastrointestinal Stroma Tumors: Recent advances in understanding of their biology. *Hum Pathol* 1999;30:1213-20 .
2. Schindler T, Bornmann W, Pellicena, et al. Structure mechanism for STI 571 inhibition of albeson tyrosine kinase. *Science* 2000; 289:1938-42.
3. Pierie JP, Choudry U, Muzikansky A, et al. The effect of surgery and grade on outcome of gastrointestinal stromal tumors. *Arch Surg* 2001;136:383-9.
4. Yao KA, Talamonti MS, Langella RL, et al. Primary gastrointestinal sarcomas: analysis of prognostic factors and results of surgical management. *Surgery* 2000;128:604-12.
5. Joensuu H, Roberts PJ, Sarlomo-Rikala M, et al. Effect of the tyrosine kinase inhibitor STI 571 in a patient with a metastatic gastrointestinal stromal tumor. *N Engl J Med.* 2001;344:1052-6.
6. Heinrich MC, Griffith DJ, Druker BJ, et al. Inhibition of c-kit receptor tyrosine kinase activity by STI 571, a selective tyrosine kinase inhibitor. *Blood* 2000;96: 925-32.
7. Reith JD, Goldblum JR, Lyles RH, et al. Extragastrintestinal (soft tissue) stromal tumors: an analysis of 48 cases with emphasis on histologic predictors of outcome. *Mod Pathol* 2000;13:577-85.
8. Miettinen M, Sarlomo-Rikala M, Lasota J. Gastrointestinal stromal tumours. *Ann Chir Gynaecol* 1998;87:278-81.
9. Mocharnuk RS. STI-571: The Next Step. Program and abstracts of the 37th Annual Meeting of the ASCO. May 14, 2001.
10. Yamada T. *Textbook of Gastroenterology*. 3rd ed. Philadelphia: Lippincott Williams & Wilkins;1999;1522.
11. Feldeman M, Scharschmidt BF, Sleisenger MH. *Sleisenger & Fordtran's Gastrointestinal and Liver Disease*. 6th ed. Philadelphia: W.B. Saunders;1998;751.
12. Miettinen M, Sarlomo-Rikala M, Sobin LH, et al. Gastrointestinal stromal tumors and leiomyosarcomas in the colon: a clinicopathologic, immunohistochemical, and molecular genetic study of 44 cases. *Am J Surg Pathol* 2000;24:1339-52.
13. Miettinen M, Lasota J. Gastrointestinal stromal tumors-definition, clinical, histological, immunohistochemical, and molecular genetic features and differential diagnosis. *Virchows Arch* 2001;438:1-12.

14. Nishida T, Hirota S. Biological and clinical review of stromal tumors in the gastrointestinal tract. *Histol Histopathol* 2000;15:1293-301.
15. Druker BJ, Sawers CL, Kantarjian H, et al. Activity of a specific inhibitor of the BCR-ABL tyrosine kinase in the blast crisis of chronic myeloid leukemia and acute lymphoblastic leukemia with the Philadelphia chromosome. *N Engl J Med* 2001;344:1038-42.
16. Longley BJ, Reguera MJ, Ma Y. Classes of c-kit activating mutation: proposed mechanisms of action and implications for disease classification and therapy. *Leuk Res* 2001;25:571-6.
17. Lux ML, Rubin BP, Biase TL, et al. Kit extracellular and kinase domain mutation in gastrointestinal stroma tumors. *Am J Pathol* 2000;156:791-5.
18. van Der Kolk DM, Vellenga E, van Der Veen AY, et al. deletion of the multidrug resistance protein MRP1 gene in acute myeloid leukemia: the impact on MRP activity. *Blood* 2000;95:3514-9.
19. Simon SM, Schindler M. Cell biological mechanisms of multidrug resistance in tumors. *Proc Natl Acad Sci U S A* 1994;91: 3497-504.
20. van Oosterom AT, Judson I, Verweij J, et al. Safety and efficacy of imatinib (STI571) in metastatic gastrointestinal stromal tumours: a phase I study. *Lancet* 2001;358:1421-3.
21. Nishida T, Nakamura J, Taniguchi M, et al. Clinicopathological features of gastric stromal tumors. *J Exp Clin Cancer Res* 2000;19:417-25.

#### 腸胃基質瘤：兩例病例報告及文獻回顧

莊伯 鄭企峰\* 廖麗瑛 施麗順\*\* 王朝欣 黃明哲\*\*\*

台北市立仁愛醫院 消化內科 \*腫瘤科 \*\*病理科  
\*\*\*台北市馬偕紀念醫院 腫瘤科

#### 摘 要

腸胃基質瘤 (GIST) 是指源自於腸胃道的基質細胞瘤，是組織基質上的原始細胞瘤。最近的研究顯示腸胃基質瘤的細胞有一種生長因子受體稱為 c-kit，是原始致癌基因 c-kit 的產物，具有酪氨酸激酶 (tyrosine kinase) 的功能。就臨床而言，腸胃基質瘤最具特異性及可運用於臨床的診斷標準是以免疫組織化學法染色

能染出 c-kit ( CD117 ) 的表現。腸胃基質瘤有必要以能染出腫瘤細胞有廣泛 CD-117 為診斷標準來重新分類。我們報告兩位復發性腸胃基質細胞瘤的女性病人，分別以手術治療其復發腫瘤 1 及 4 年卻仍有新腫瘤生成。她們分別改用了口服 STI571 ( glivec ) 的治療。Glivec 是一種小分子的高度專一性靶標藥物，競爭性地抑制細胞膜訊息傳遞酵素 ( 酪胺酸激酶 ) 的活性。依照過去的使用報告而言，它是非常安全的。我們的這兩位病人有一位腫瘤消失，過著正常的生活，另一位卻死亡。僅就目前能獲得的文獻來檢視這個結果。

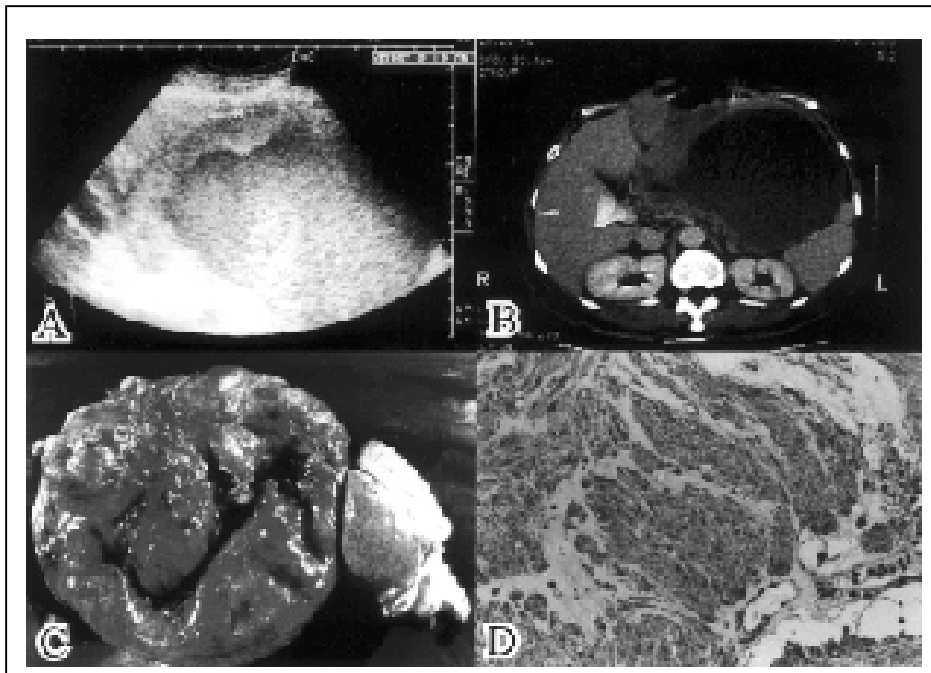


Fig.1. The 53 y/o woman, complaining epigastralgia and fullness for months, went to doctors due to palpable abdominal mass. Studies showed a huge cystic tumor with irregular thick wall between stomach, pancreas and spleen (A,B: May 8, 2000). The tumor was 17.5x16.5x6.2 cm<sup>3</sup> in size, soft tissue origin, and diffuse positive CD 117 stain (C,D: May 15, 2000).



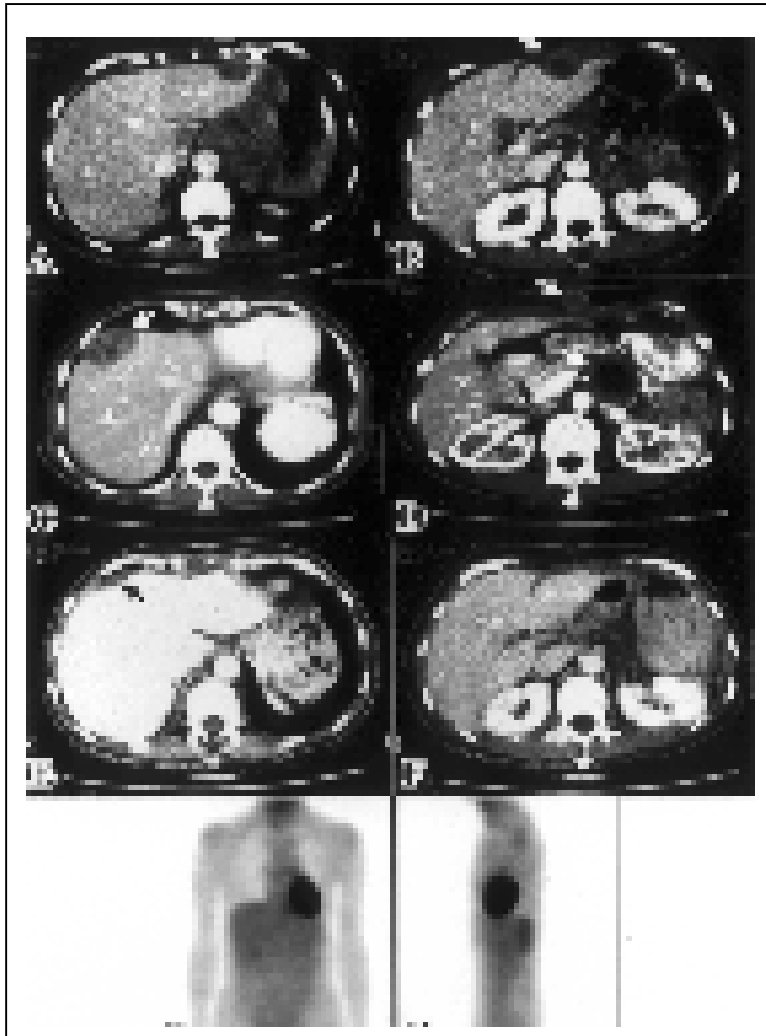


Fig.2. Progressive subcutaneous nodules and abdominal tumor growth and hepatic metastasis (white arrow) after debulking and radiation therapy. (A,B: Jan. 10, 2001, before debulking; and C,D: Mar. 21, 2001, before glivec therapy ) Only hepatic tumor scar (black arrow) visible in the following CT after glivec therapy. (E,F: Jun. 7. 2001) No tumor 18 fluorodeoxyglucose uptake was found in the following 18FDG-PET scan examinations on Apr. 26, 2001 (after 18 days' glivec therapy, Adelaide hospital, not shown) and Jan. 4, 2002 (G,H, Jen-Ai Hospital).

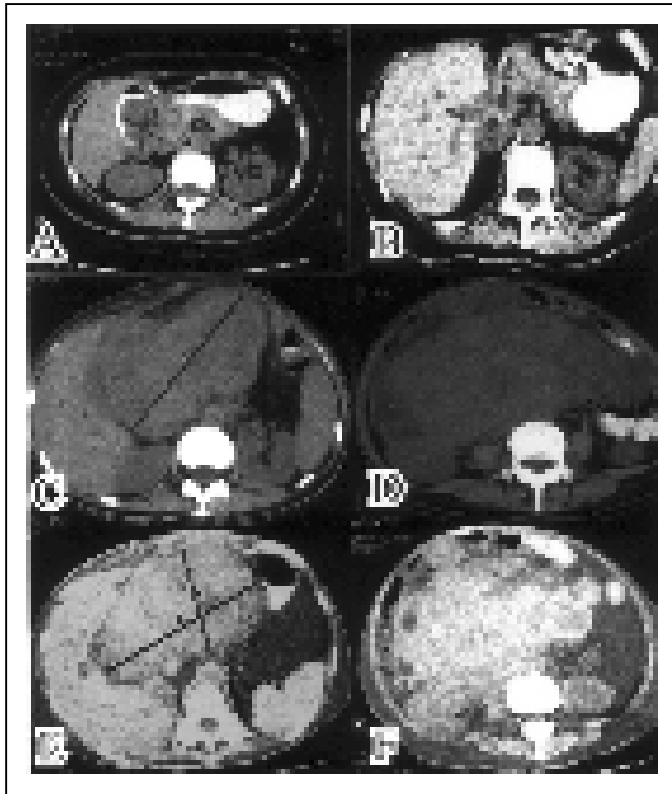


Fig.3. The 45 y/o woman went to doctors due to tarry stool for 10 days. CT study showed a duodenal tumor (A: Mar. 20, 1997). The tumor was 7.1 x 5.3 x 4.2 cm<sup>3</sup> in size. Recurrence happened after the first surgery (B: May 13, 1998, the 14th month) and debulking (C,D: Apr. 20, 2001, the 49th month). The big recurrent tumors had no response to 54 days' glivec therapy (E,F: Jul. 13, 2001, the 52th month). She died on Jul. 19, 2001, the 60th day after her first glivec therapy.