

# Lemierre's Syndrome with *Fusobacterium* *Necrophorum* Bacteremia : A Report of Two Cases in Taiwan

Chih-Hung Lin<sup>1</sup>, Ming-Huang Chiu<sup>1</sup>, Li-Chun Chen<sup>2</sup>, and Cheng-Hua Huang<sup>2,3</sup>

<sup>1</sup>Section of Respiratory Care and Chest Medicine,

<sup>2</sup>Section of Infectious Diseases, Department of Internal Medicine,  
Cathay General Hospital, Taipei, Taiwan

<sup>3</sup>Fu Jen Catholic University College Of Medicine

## Abstract

Lemierre's syndrome—the forgotten disease, is a suppurative thrombophlebitis of the internal jugular vein caused by *Fusobacterium necrophorum* bacteremia, in the antecedent presence of oropharyngeal infection mimicking viral pharyngitis and it can be complicated by metastatic abscesses formation, most commonly in the lungs. Two cases of Lemierre's syndrome are presented to remind physicians about the unique clinical pictures of the forgotten disease in Taiwan. Early recognition and appropriate antibiotic treatment will cure this possibly life-threatening disease. ( J Intern Med Taiwan 2007; 18: 365- 370 )

**Key Words** : Lemierre's syndrome, *Fusobacterium necrophorum* bacteremia, Septic pulmonary embolism, Anaerobic bacterial infection

## Introduction

Lemierre's syndrome, also known as a postanginal septicaemia, is a rare disease process occurring after an episode of fever and acute tonsillopharyngitis. It is characterized by a suppurative infection of the lateral pharyngeal space, associated with *Fusobacterium necrophorum* bacteremia and septic

thrombophlebitis of the internal jugular vein, sometimes leading to metastatic septic embolization of the lung and subsequent abscesses formation. In medical literatures, this disease was more frequently reported in the pre-antibiotic era, and is now a rare sequential complication of pharyngitis. Here we report two cases of *F. necrophorum* bacteremia and fulfilled the characteristics of Lemierre's syndrome.

## Case Report

### Case 1

A previously healthy 21 year-old man presented with a five-day history of sore throat, lethargy, fever and rigors. Three days prior to this entry, he was diagnosed as an influenza-like illness (ILI). Physical examination on admission, the patient appeared acutely ill, with a body temperature of 39.3 °C (oral), blood pressure of 156/60 mmHg, pulse rate of 118 beats per minute, and a respiratory rate of 18 breaths per minute. A tender swelling area was evident below the angle of the left side mandible anteriorly to the upper left sternocleidomastoid muscle. The chest and abdominal examination revealed no significant abnormality.

Initial laboratory results were as follows: hemoglobin 11.6 g/dL; white cell count  $9.290 \times 10^3 / \mu\text{L}$  (90.9 % neutrophils, 6.1 % lymphocytes, and 2.9 % monocytes); platelet count  $177 \times 10^3 / \mu\text{L}$ . C-reactive protein was 15.8 mg/dL (normal range < 0.05); alkaline phosphatase 227 IU/L (normal range = 30-120); aspartate transaminase 33 IU/L (normal range = 5-35); alanine transaminase 50 IU/L (nor-

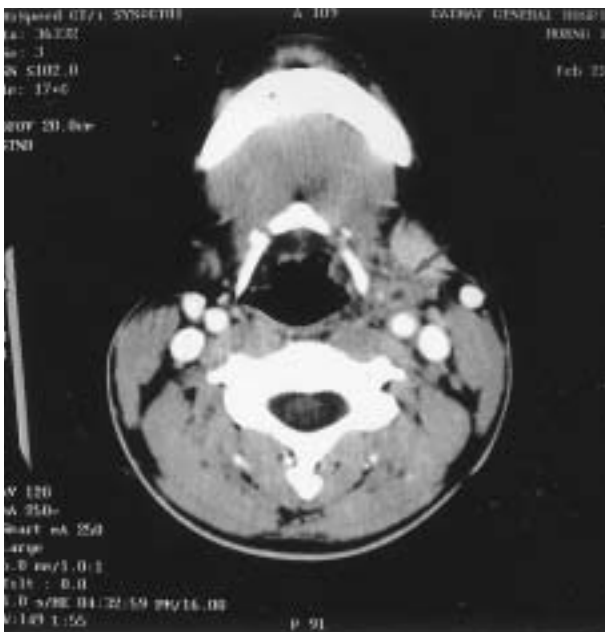

Fig.1. Neck CT showing the left side parapharyngeal space abscess formation (arrow) in case 1.

mal range = 5-35). Urea and electrolyte levels were within normal limits.

The chest X-ray was normal, while the neck computed tomography (CT) image revealed left cervical lymphadenitis and an abscess formation in the left side parapharyngeal space close to the submandibular gland (Figure 1).

The patient's fever defervescenced down to normal on the sixth hospital day after the treatment with intravenous amoxicillin/clavulanic acid, and he was subsequently discharged after a total ten-day treatment. Blood culture done on the day of emergency room visit yielded *F. necrophorum*.

### Case 2

A previously healthy 22 year-old man with a two-day history of sore throat, non-productive cough, lethargy and fever with antecedent rigors. Severe pleuritic pain had also developed on the first admission day. Mild right side neck discomfort was experienced. Upon physical examination, the patient appeared acutely ill, with a body temperature of 37.9 °C, blood pressure of 92/59 mmHg, pulse rate of 117 beats per minute, and a respiratory rate of 18 breaths per minute. Pus exudates were found over tonsillar surface bilaterally. No tenderness or swelling was evident on either side of the neck, mandible or sternocleidomastoid muscles. There was no neck lymphadenopathy. On chest auscultation, there were crackles over the left lower lung field.

Results of the hematological and biochemical investigation were as follows. Peripheral blood examinations: hemoglobin 13.4 g/dL; white blood cell count  $26.86 \times 10^3 / \mu\text{L}$  (89.8 % neutrophils, 5.8 % lymphocytes, and 4.0 % monocytes); platelet count  $257 \times 10^3 / \mu\text{L}$ . C-reactive protein was 24.574 mg/dL. Liver function test: alkaline phosphatase 115 IU/L; aspartate transaminase 58 IU/L; alanine transaminase 31 IU/L. Urea and electrolyte levels were within normal limits.

The plain chest X-ray film showed increased density in the retrocardiac region of the left lung and blunt-

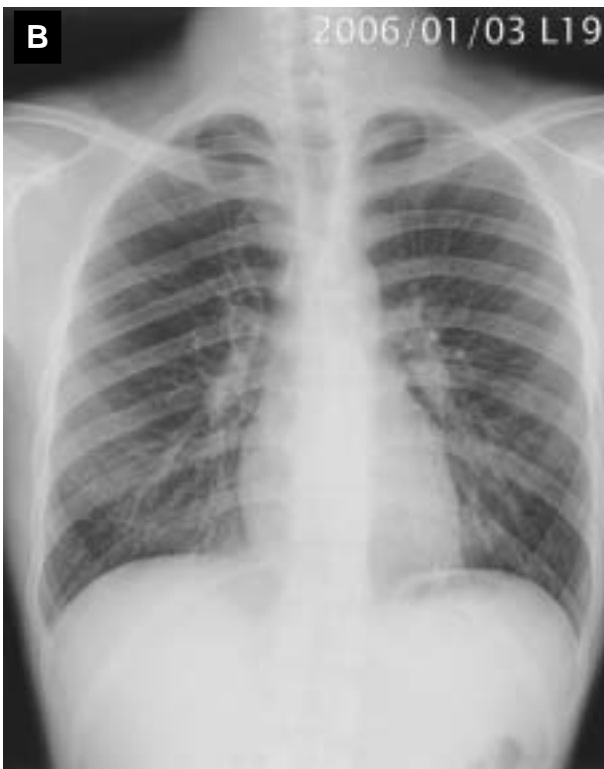
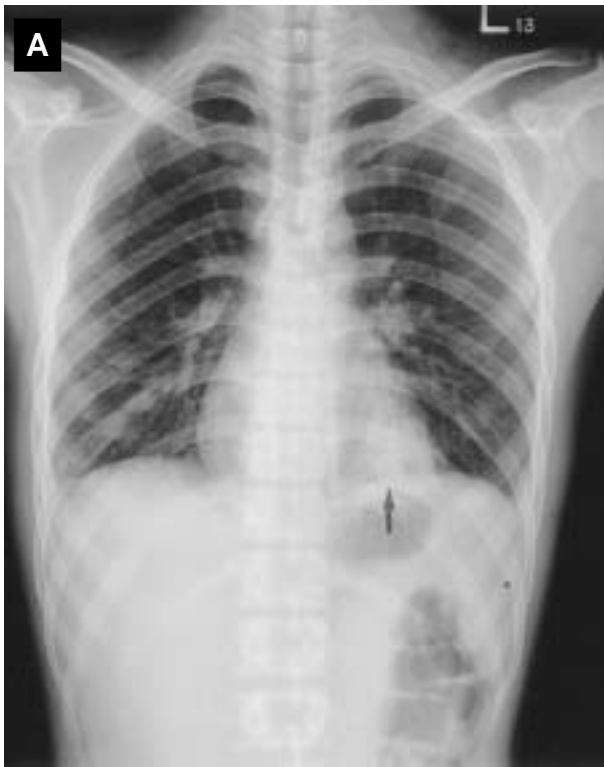
Fig.2A.PA view chest X-ray demonstrating increased density in the retrocardiac region ( arrow ) and bilateral costophrenic angle blunting in case 2.

Fig.2B.PA view chest X-ray after antibiotic treatment for 4 weeks showing resolution of left lower lobe lesion.

ing of bilateral costophrenic angles ( Figure 2A ). Chest CT revealed multiple bilateral lung parenchymal lesions and a cavitating mass in the left lower lobe with a phenomenon of wall enhancement ( Figure 3 ). The Neck CT scan revealed a filling defect in the right internal jugular vein ( Figure 4 ). Color Doppler ultrasonography was performed on the tenth hospital day, revealing a spontaneous contrast echo

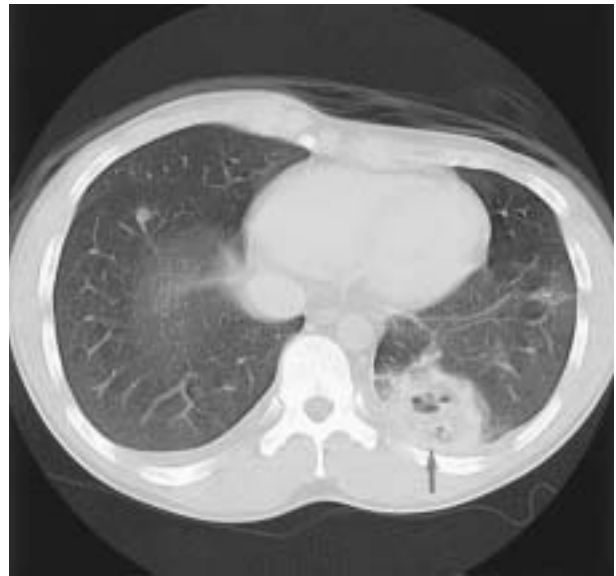

Fig.3.Chest CT showing the left lower lobe abscess formation due to septic embolism ( arrow ) in case 2.

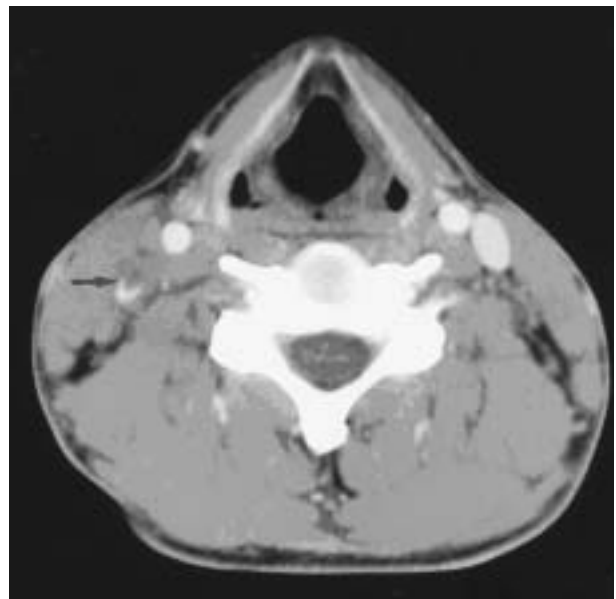


Fig.4.Neck CT illustrating the filling defect ( curve-shaped ) of right side internal jugular vein ( arrow ) indicating a thrombus formation in case 2.

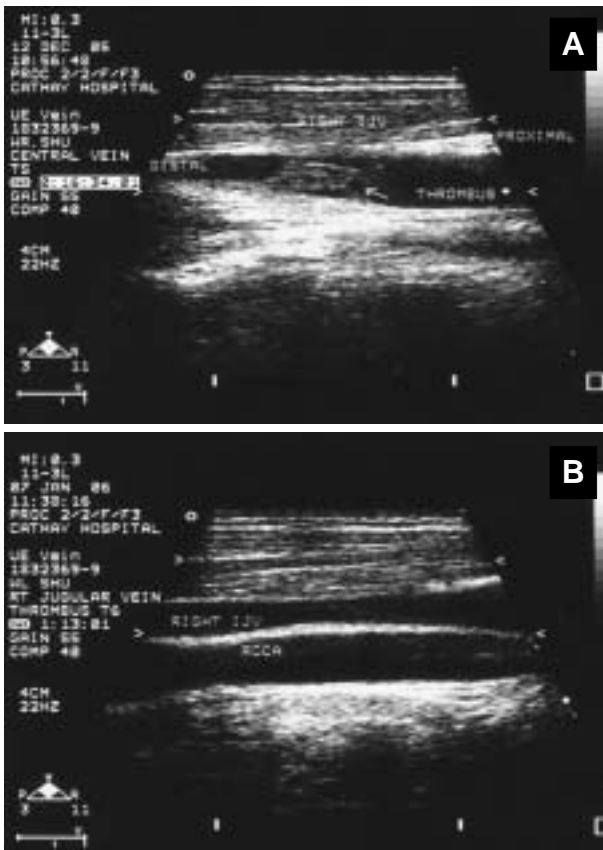


Fig.5A. Doppler ultrasonography of the right side internal jugular vein on the tenth hospital day showing a spontaneous contrast echo indicative of a thrombus in case 2.

Fig.5B. Doppler ultrasonography of the right side internal jugular vein 30 days after the initial showed complete resolution of the thrombus.

in the right internal jugular vein, indicative of an established thrombus ( Figure 5A ). His blood culture on the first hospital day yielded *F. necrophorum*.

The fever persisted until the sixth hospital day in spite of the treatment with intravenous amoxicillin/clavulanic acid. Patient was discharged 4 weeks later with evidence of resolution on chest X-ray ( Figure 2B ) and prescribed sequential oral antibiotics for another one week. Follow-up Doppler duplex ultrasonograph examination disclosed a patent left internal jugular vein without evidence of thrombus formation ( Figure 5B ).

## Discussion

André Lemierre was the first man to character-

ize this illness in 1936<sup>1</sup>. The classical clinical manifestation was pharyngotonsillitis, followed by "cord signs": swelling and tenderness along the sternocleidomastoid muscle<sup>2</sup>, indicating septic thrombophlebitis of the internal jugular vein. Within a week, high fever, rigors and metastatic embolic abscesses, usually in the lungs, bones and liver occurred, and patients typically died within 7-15 days after onset of symptoms. Among the 20 cases reported in his literature, 18 cases died because of this disease.

Case 1 was considered a case of Lemierre's syndrome with primary infection and local invasion of lateral pharyngeal space<sup>3</sup>. Although no evidence of internal jugular vein thrombophlebitis or metastatic infection was noticed, neck CT scan showed obvious abscess formation and the etiology was discovered by blood culture. In contrast, case 2 presented with evidence of internal jugular vein thrombophlebitis without typical "cord signs" of the neck. Metastatic infection in the lung constituted the chest CT picture of multiple septic pulmonary embolisms and an abscess formation on the left lower lobe. Although we did not take the risk of lung aspiration, the etiology was found by blood culture and the patient improved after antibiotic treatment.

In 1990's, it was suggested that the resurgence of this disease in western countries was a consequence of more restricted use of antibiotics in the treatment of upper respiratory tract infection<sup>4,5</sup>. On the contrary to this idea is the report by Hagelskjaer, where 33 % of a patient cohort diagnosed with Lemierre's syndrome had received antibiotic treatment prior to their admission<sup>6</sup>. Therefore, it may be erroneous about the fact that an empiric antimicrobial therapy can reliably interrupt the natural course of this infection. Although continuing education on judicious use of antibiotics for the treatment of upper respiratory tract infection had been widely advocated to health-care providers in Taiwan, which make the possibility of the resurgence of Lemierre's syndrome, it may be due to improved laboratory diagnostic technique and clin-

ical microbiological methods that ultimately increase the probability of detecting anaerobic organisms such as *F. necrophorum*.

*Fusobacterium* species is a normal inhabitant of the oral cavity. Its characteristic virulence stems from a lipopolysaccharide not shared by most of the other anaerobes of the oral cavity and upper respiratory tract<sup>7</sup>. Clinical or subclinical icterus may be due to the cholestatic effect of the lipopolysaccharide endotoxin released by *Fusobacterium necrophorum*<sup>8</sup>. When a patient initially presents to the clinicians, the appearance of the pharynx can vary from mild tonsillar injection, to a severe exudative tonsillitis or peritonsillar abscess formation.

Internal jugular venous thrombophlebitis can only be confirmed by imaging techniques. Doppler ultrasonography is the most convenient and also a noninvasive technique, with the added advantage of not exposed to radiation. However imaging beneath the clavicle and mandible is poor, and it is difficult to detect a fresh thrombus with low echogenicity<sup>9</sup>. As in the cases presented, we urged strongly that this examination better be performed at least 10 days after the onset symptom of hectic fever. CT of neck and lungs is a more feasible and sensitive examination, but increasing the chance of exposure to radiation<sup>10</sup>.

With regard to the antimicrobial therapy, macrolides, quinolones, gentamicin and antistaphylococcal penicillins were all considered inadequate. In vitro resistance to penicillin due to beta-lactamase production has also been reported<sup>11</sup>, while sensitivity to clindamycin and metronidazole remained consistently. Monotherapy with metronidazole is not recommended because of the high likelihood of aerobic and anaerobic mixed infection; however most reviewers preferred the use of high dose penicillin plus metronidazole, or monotherapy with clindamycin<sup>12</sup>. According to the findings from a susceptibility testing review on anaerobic lung abscess<sup>13</sup>, anaerobic pathogen resistance to penicillin in Taiwan have increased as high as 15 %, compared with only

less than 5 % resistance to metronidazole. Therefore, we recommend the use of beta-lactam/beta-lactamase inhibitors as the first choice of the treatment of Lemierre's syndrome. As to the duration of antibiotic treatment, 2 to 6 weeks was recommended with close follow up of ultrasonographic study. The prolonged course of therapy may be needed for a thrombus with fibrin clot formation of the jugular vein to obtain an eradication of *F. necrophorum* within the clot. We considered the use of Doppler duplex ultrasonography as a tool for follow up. Sonographic resolution of the thrombus may be indicative of a successful treatment, but further case studies are required. Anticoagulant therapy for the septic thrombophlebitis is not recommended in most papers reported in the literature.

In conclusion, unfamiliarity with the symptoms and signs of Lemierre's syndrome may mix up the initial diagnosis of Lemierre's disease to a viral pharyngitis. The clinical lesson is therefore straightforward: when a previously healthy young patient with a history of antecedent pharyngitis, but with a clinical picture of aching over neck or chest cage ( neck pain in case 1 and chest pain in case 2 ), do keep in mind on the reemerging disease of Lemierre's syndrome.

## References

1. Lemierre A. On certain septicemias due to anaerobic organisms. *Lancet* 1936; 1: 701-3.
2. Tovi F, Fliss DM, Noyek AM. Septic internal jugular vein thrombosis. *J Otolaryngol* Dec 1993; 22: 415-20.
3. Chirinos JA, Lichtstein DM, Garcia J, et al. The evolution of Lemierre syndrome: report of 2 cases and review of the literature. *Medicine ( Baltimore )* Nov 2002; 81: 458-65.
4. Lustig LR, Cusick BC, Cheung SW, et al. Lemierre's syndrome: two cases of postanginal sepsis. *Otolaryngol Head Neck Surg* Jun 1995; 112: 767-72.
5. Leugers CM, Clover R. Lemierre syndrome: postanginal sepsis. *J Am Board Fam Pract* Sep-Oct 1995; 8: 384-91.
6. Hagelskjaer Kristensen L, Prag J. Human necrobacillosis, with emphasis on Lemierre's syndrome. *Clin Infect Dis* Aug 2000; 31: 524-32.
7. Bekelman JE, Francis JS, Berliner AR, et al. Lemierre's variant. *Lancet Infect Dis* Aug 2004; 4: 518.
8. Ockrim J, Kettlewell S, Gray GR. Lemierre's syndrome. *J R Soc*

- Med Sep 2000; 93: 480-1.
9. Golpe R, Marin B, Alonso M. Lemierre's syndrome (necrobacillosis). Postgrad Med J Mar 1999; 75: 141-4.
10. Sreaton NJ, Ravenel JG, Lehner PJ, et al. Lemierre syndrome: forgotten but not extinct--report of four cases. Radiology Nov 1999; 213: 369-74.
11. Brazier JS, Hall V, Yusuf E, et al. Fusobacterium necrophorum infections in England and Wales 1990-2000. J Med Microbiol Mar 2002; 51: 269-72.
12. Eykyn SJ. Necrobacillosis. Scand J Infect Dis Suppl 1989; 62: 41-6.
13. Wang JL, Chen KY, Fang CT, et al. Changing bacteriology of adult community-acquired lung abscess in Taiwan: Klebsiella pneumoniae versus anaerobes. Clin Infect Dis Apr 1 2005; 40: 915-22.

## Lemierre's Syndrome 合併梭狀桿菌菌血症： 台灣二病例報告

林志鴻<sup>1</sup> 邱銘煌<sup>1</sup> 陳立群<sup>2</sup> 黃政華<sup>2,3</sup>

國泰綜合醫院 內科部 <sup>1</sup>呼吸胸腔科 <sup>2</sup>感染科  
<sup>3</sup>輔仁大學醫學院醫學系

### 摘 要

Lemierre's syndrome 是急性咽喉炎合併化膿性內頸靜脈血栓靜脈炎，通常與梭狀桿菌菌血症 (*Fusobacterium necrophorum* bacteremia) 有關，而且常發生轉移性膿瘍，尤其是肺膿瘍最常見。其初期臨床表現酷似病毒性咽喉炎，所以在此提出二病例報告以提醒臨床醫師及早發現給予適當治療以扭轉此可能致命之疾病。