

# The Early Presentation of Creutzfeldt-Jacob Disease : Two Cases Report in Middle Taiwan

Chieh-Sen Chuang, Shey-Lin Wu, Min-Chih Lo,  
Ming-Ching Shen<sup>1</sup>, and Tsun-Jung Liu<sup>2</sup>

*Department of Neurology, <sup>1</sup>Division of Hematology and Oncology,  
<sup>2</sup>Division of Infectious Disease, Department of Internal Medicine,  
Changhua Christian Hospital, Changhua, Taiwan*

## Abstract

**BACKGROUND :** Creutzfeldt-Jacob disease ( CJD ) is the most common transmissible human spongiform encephalopathy. We describe the early presentation of clinical course and special diagnostic findings of two sporadic CJD in middle Taiwan. **CASES :** Both patients presented with non-specific symptoms such as poor appetite, forgetful, change in personality, sleep disorder, and dizziness before seeking medical advice. Afterwards the two patients had impairment of multiple neurologic symptoms such as visual disorder, myoclonic jerks, ataxia and dysarthria. Magnetic resonance image ( MRI ) of brain in diffusion-weighted image ( DWI ) showed ribbon-like area involving cerebral cortex in the early stage. Electroencephalography revealed lateralized epileptiform discharges. Deterioration in their clinical condition was progressing to a dependent state within 4 to 6 months. The treatment remains palliative including anticonvulsant for myoclonic jerks and rehabilitation. **CONCLUSION :** The early features of CJD can be non-specific. The brain image findings and clinical presenting attributes of patients provide diagnostic indications. Early diagnosis is important for patients, family and health-care providers. ( J Intern Med Taiwan 2008; 19: 78- 82 )

**Key Words :** Creutzfeldt-Jacob disease, CJD, Prion disease, Diffusion-weighted image of MRI

## Introduction

Creutzfeldt-Jacob disease is a rare and invariably fatal neuro-degenerative disorder. Part of a larger family of diseases called 'Prion diseases' or subacute spongiform encephalopathies (SSE's), this is a transmissible, neuro-degenerative disorder with distinct clinical and pathological features<sup>1</sup>. Jacob first described this illness in 1921<sup>2</sup>. He described a progressive disease of the cortex, basal ganglia, and spinal cord that developed in middle-aged and elderly adults, in which rapidly progressive and profound dementia is associated with diffuse myoclonic jerks, and a variety of other neurologic abnormalities. This disease appeared in all parts of the world with an annual incidence of one to two cases per million of population. About 180 cases have been registered in the CJD registry in Taiwan in front of April 2007. The clinical features, aside from dementia, are those of pyramidal tract disease ( i.e. weakness of the limbs with reflex change ), extrapyramidal signs ( i.e. tremors, rigidity, dysarthria, and slowness of movements ), and stimulus sensitive myoclonus. The pathologic condition is essentially degenerative with grossly evident cerebral atrophy. Microscopic findings are spongy appearance, loss of neurons, and prominent astrocytosis. The cortex and basal ganglia are most affected.

### Case 1

This case is a 79-year-old man who was admitted because of falling from bicycle and persistently unstable gait. His family members had noted a change in his personality and depress mood. He became poor appetite, forgetful, calm, dull, withdrawn and somatic complains two months before. Two weeks prior to admission, his gait had become unsteady. He was a farmer. There was no significant past medical history or family history. Physical examination revealed left side limbs ataxia. He was disoriented, emotionless, inattentive, and with impaired memory. He had bladder and bowel incontinence sometimes. Full blood

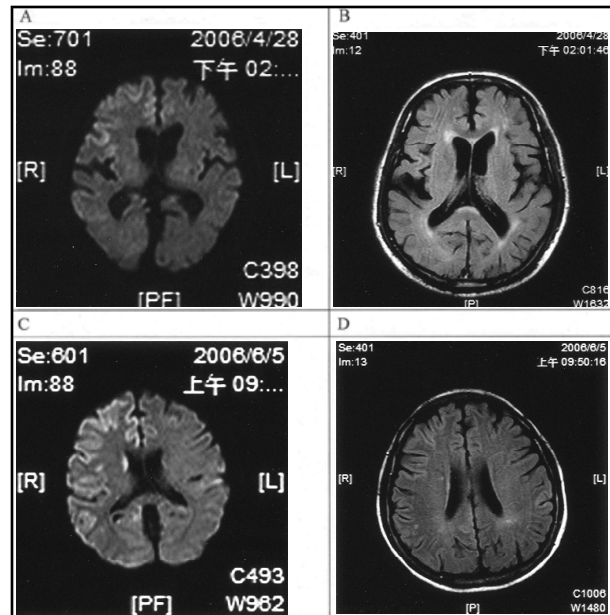


Fig.1. diffusion weight image of brain MRI on case 1 (A) and case 2 (C) revealed abnormal high signal intensity lesions on right cerebral cortex, otherwise the caudate nucleus of case 2 was noted high signal intensity also. The MRI findings of proton density weighted images on case 1 (B) and case 2 (D) were no abnormalities.

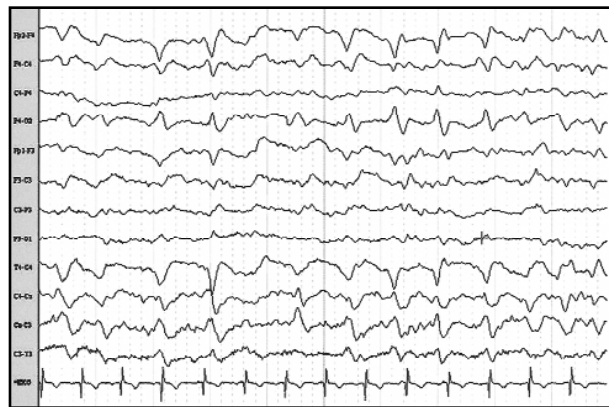


Fig.2. One month later after onset, the findings of electroencephalography of case 1 revealed periodic complexes of sharp and slow wave activities over right hemisphere, at intervals of 0.5 second to 2.0 seconds.

count, electrolyte, vitamin B12 serum level and thyroid function test were normal. Screenings of rapid plasma-reagin (RPR) test for neurosyphilis was negative. The CSF study revealed no pleocytosis and normal protein level. The findings of brain MRI revealed extensive abnormal asymmetrical gyriform high sig-

nal intensity lesions seen on the DWI study ( figure 1 ). The EEG reports were generalized 2-3 Hz slow waves. In addition, spontaneous and startle myoclonic jerks and altered mental status were noted one month later. The EEG findings were periodic complexes of sharp and slow wave activities, at intervals of 0.5 second to 2.0 seconds ( figure 2 ). He remained in a vegetative state 4 months later.

### Case 2

This case is a 56-year-old woman who was noted progressive disturbance of consciousness with left limbs involuntary movement for one and half months before admission. She was diagnosed with pancytopenia exclude myelodysplastic syndrome due to refractory anemia on Mar. 2004. The bone marrow histology reports were hypocellular marrow. Thus she received blood and platelet transfusion many times.

She presented non-specific symptoms including poor appetite, blurred vision, insomnia in early 2006 with 3 to 4 months. Additionally, she was found easily frightened by abrupt sound. The neurologic examination showed dysarthria, limbs rigidity, action tremor in the upper extremities, and truncal ataxia with a broadbased gait. Spontaneous and startle myoclonic jerks of limbs were noted. Vitamin B12, folate, thyroid function test, RPR, and serum cortisol level were normal. The reports of cerebrospinal fluid were normal protein level and no pleocytosis. The MR brain scan, including diffusion-weighted imaging ( DWI ), show abnormal high signal intensity lesions on right cerebral cortex ( figure 1 ). The electroencephalography revealed periodic 0.5-2 Hz lateralized epileptiform discharges over the right hemisphere.

## Discussion

Creutzfeldt-Jacob disease ( CJD ) is the human prion disease which is neurodegenerative disease with long incubation. Approximately one case of sporadic CJD occurs per 1,000,000 population per year with a worldwide distribution. In Taiwan, surveillance system of CJD has been setup since 1997 at Department

of Health, Executive Yuan. Till end of April 2007, a total of 180 cases had been confirmed and registered. The prevalence rate was 0.48 per million population in 2006. Diagnosing CJD is a challenging task. Antemortem diagnosis is usually difficult. Presumptive diagnosis is based on clinical and available laboratory tests and a definite diagnosis can only be established by a neuropathologic study, most reliably performed postmortem. Rapidly progressive mental deterioration and myoclonus are the two cardinal clinical manifestation of sporadic CJD. The case 1 was admitted due to left side limbs ataxia and mild mental decline. The important clinical findings of myoclonus and periodic sharp wave complexes of EEG were not noted until one month later. The duration of onset and admission was about 2 months. The MRI findings of T2 and proton density weighted images were no abnormalities. But the findings of DWI showed right cerebral cortical high signal ( figure 1 ). The case 2 was sent to hospital because of limbs jerk and disturbance of cognition. The EEG findings were periodic sharp-wave complexes with right hemisphere predominant.

MR imaging has shown promising developments in increasing the sensitivity of diagnosis. On T2W and proton density images, areas of hyperintensity are seen in caudate nucleus, putamen, globus pallidus and thalamus<sup>3</sup>. The MRI of these two cases reveal abnormal asymmetrical high signal intensity lesions only on the DWI study and not on the T2WI/FLAIR. It suggested that DWI is more sensitive than T2-weighted MRI and FLAIR for the detection of CJD, especially in the early stages of disease, before the onset of characteristic clinical findings such as myoclonus and periodic sharp wave complexes seen on electroencephalogram. Demaerel et al reported three patients with autopsy-proved CJD. They stated cortical involvement on DWI promoted the diagnosed of CJD at an early stage, even no abnormalities on T2- and proton density weighted images<sup>4</sup>.

The EEG findings of case one was generalized

2-3Hz slow wave with right hemisphere predominant after 2 months onset, and periodic sharp wave complexes (PSWCs) was observed one month later. However, the typical EEG findings was recorded on case two after one and half months onset. It indicated PSWCs may not be recorded in the initial stages of the illness, and serial EEG recording may be useful in patients suspected of having sporadic CJD when initial EEG recordings are negative. PSWCs have a very high specificity for the diagnosis of sCJD. Steinhard's study were found to have a sensitivity and specificity of 64 and 91 percent. Otherwise, PSWCs also appropriate to differentiate probable sporadic CJD from other prion diseases<sup>5</sup>.

Neuropathology is the definitive test for diagnosis of CJD, and features are characteristic and quite specific. The most consistent histological abnormality is a spongiform changes, neuronal loss, reactive astrocytosis in the grey matter. However, biopsy is an invasive procedure, and it is arguably reasonable only in cases for which there is a possibility of an otherwise undiagnosed and potentially treatable illness. In majority of cases, a highly probable diagnosis can be made using typical features and other investigations. Spongiform vacuolation can occur in other diseases. Neurodegenerative diseases associated with severe neuronal loss produce status spongiosus as a common feature in end stages. The conditions where spongiform change may be seen are Alzheimer's disease, metabolic encephalopathy, hypoxia, and neuronal storage disorders.

The case 2 was diagnosed with pancytopenia, thus she received blood transfusion many times. Human transmission of CJD by blood transfusion has never been conclusively shown. Available epidemiologic studies suggest that a history of preceding transfusion does not increase the risk of developing sporadic CJD<sup>6,7</sup>. A reanalysis of case-control studies of CJD did not suggest any risk from blood transfusions<sup>8</sup>. Heye et al. could not find evidence of transmission of CJD with blood products derived from a

donor who died from CJD<sup>9</sup>. There is few report of development of sporadic CJD in a patient several months after albumin infusions<sup>10,11</sup>; however, this is likely to represent a fresh sporadic CJD rather than transfusion-acquired case.

No effective treatment has been identified for Creutzfeldt-Jakob diseases, which are uniformly fatal. Care for patients with Creutzfeldt-Jakob disease is supportive. Some case reports of stabilization or improvement following treatment with amantadine, acyclovir, interferons, and amphotericin B have not been confirmed. Prion diseases are associated with the conversion of the  $\alpha$ -helix rich prion protein (PrP<sup>C</sup>) into a  $\beta$ -structure-rich insoluble conformer (PrP<sup>Sc</sup>) that is thought to be infectious. The new potential therapeutic target includes the steps in the conversion of PrP<sup>C</sup> to PrP<sup>Sc</sup> and the transport of PrP<sup>Sc</sup> to the nervous system<sup>12,13</sup>.

## Conclusion

Creutzfeldt-Jakob disease is a progressive neurologic condition with a fatal outcome. The early features of CJD can be varied and non-specific. The early brain image findings and clinical presenting feature of patients provide crucial diagnostic clues. Early diagnosis is important for patients, family and health-care providers.

## References

1. Wehl CC, Roos RP. Creutzfeldt-Jakob disease, new variant creutzfeldt-jakob disease, and bovine spongiform encephalopathy. *Neurol Clin* 1999; 17: 835-59.
2. Katscher F. It's Jakob's disease, not Creutzfeldt's. *Nature* 1998; 393: 11.
3. Schroter A, Zerr I, Henkel K, et al. Magnetic Resonance Imaging in the clinical diagnosis of Creutzfeldt-Jacob disease. *Arch Neurol* 2000; 57: 1751-7.
4. Demaerel P, Heiner L, Robberecht W, et al. Diffusion-weighted MRI in sporadic Creutzfeldt-Jakob disease. *Neurology* 1999; 52: 205-8.
5. Steinhoff BJ, Zerr I, Glatting M, et al. Diagnostic value of periodic complexes in Creutzfeldt-Jakob disease. *Ann Neurol* 2004; 56: 702-8.
6. Vamvakas EC. Risk of transmission of Creutzfeldt-Jakob disease by transfusion of blood, plasma, and plasma derivatives. *J*

- Clin Apher 1999; 14: 135-43.
7. Hewitt PE, Llewelyn CA, Mackenzie J, Will RG. Creutzfeldt-Jakob disease and blood transfusion: results of the UK Transfusion Medicine Epidemiological Review study. Vox Sang 2006; 91: 221-30.
  8. Wientjens DPWM, Davanipour Z, Hofman A, et al. Risk factors for Creutzfeldt-Jakob disease: a reanalysis of case-control studies. Neurology 1996; 46: 1287-91.
  9. Heye N, Hensen S, Muller N. Creutzfeldt-Jakob disease and blood transfusion. Lancet 1994; 343: 198-9.
  10. Patry D; Curry B; Easton D; Mastrianni JA; Hogan DB. Creutzfeldt-Jakob disease ( CJD ) after blood product transfusion from a donor with CJD. Neurology 1998; 50: 1872-3.
  11. Ricketts MN, Cashman NR, Stratton EE, ElSaadany S. Is Creutzfeldt-Jakob disease transmitted in blood? Emerg Infect Dis 1997; 3: 155-63.
  12. Korth, C, Peters, PJ. Emerging pharmacotherapies for Creutzfeldt-Jakob disease. Arch Neurol 2006; 63: 497-501.
  13. Eghiaian F, Grosclaude J, Lesceu S, Debey P, Doublet B, Treguer E, Rezaei H, Knossow M. Insight into the PrPC $\rightarrow$ PrPSc conversion from the structures of antibody-bound ovine prion scrapie-susceptibility variants. Proc Natl Acad Sci USA. 2004; 101: 10254-9.

## 庫賈氏症的早期表現：中台灣兩病例報告

莊介森 巫錫霖 羅敏智 沈銘鈞<sup>1</sup> 劉尊榮<sup>2</sup>

彰化基督教醫院 神經科<sup>1</sup> 血液腫瘤科<sup>2</sup> 感染科

### 摘要

庫賈氏症是常見的傳染性人類海綿樣腦病變，臨床的表現為進展快速的智能退化而成為植物人狀態。我們在此報告兩例在早期診斷的庫賈氏症個案，這兩位個案在初期皆有食慾不振、健忘、人格改變、失眠、頭暈等非典型的症狀，之後表現視覺障礙、肌震顫、運動失調、口齒不清的神經學表現。磁振造影除了腦部萎縮之外在擴散影像可見到大腦皮質有彩帶樣高信號表現，而腦波在初期是瀰漫性慢波，但中後期則可見癲癇樣放電的銳波，兩位個案在發病後約四到六個月為完全失能的狀態。庫賈氏症初期症狀不典型，但發病後進展快速而且又具有傳染性，因此早期的診斷對患者本身、家屬、醫護人員或看護者皆有很重要的意義。