

Pancreatic Insulinoma Presenting with Episodes of Hypoinsulinemic Hypoglycemia in Elderly — A Case Report

Chieh-Hsiang Lu¹, Shih-Che Hua¹, and Chung-Jung Wu^{2,3}

¹*Division of Endocrinology and Metabolism of Internal Medicine,
Chia-Yi Christian Hospital, Chia-Yi, Taiwan;*

²*Division of Endocrinology and Metabolism of Internal Medicine,
Chia-Yi Veterans Hospital, Chia-Yi, Taiwan;*

³*Graduate Institute of Natural Healing Science, Nanhua University,
Dalin Town, Chia-Yi, Taiwan*

Abstract

We report a rare case of pancreatic islet cell tumor (insulinoma) presenting with hypoinsulinemic hypoglycemia in an elderly man by laboratory diagnosis. Insulinoma is characterized by spontaneous fasting hypoglycemia and its diagnosis relies on inappropriately increased insulin levels during episode of hypoglycemia and/or high insulin/glucose ratio. This report highlighted that the diagnosis of insulinoma or islet cell tumor cannot be excluded by hypoinsulinemic hypoglycemia absolutely. Further analytic measurements for cross-reacting insulin or determination of proinsulin or insulin-like growth factor levels should be considered when highly suspected insulinoma or documented pancreatic nodule was found in patients with hypoglycemic episode. (J Intern Med Taiwan 2008; 19: 432-436)

Key Words : Hypoinsulinemia, Hypoglycemia, Insulinoma

Introduction

Islet cell tumor or insulinoma is characterized by spontaneous fasting hypoglycemia. Its diagnosis

relies on inappropriately increased insulin levels ($>6 \mu$ IU/ml) during episodes of hypoglycemia (fasting plasma glucose < 45 mg/dl), and/or high insulin/glucose ratio (IGR > 0.3) during episode of hy-

poglycemia or supervised 72-h fasting test¹. Occasionally, islet cell tumor may be presented with episodes of hypoglycemia without hyperinsulinemia

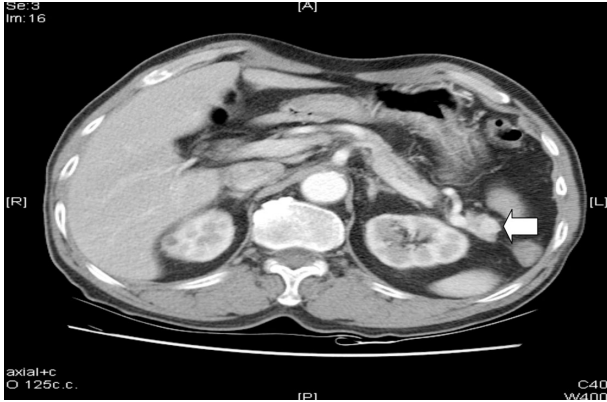

Fig.1. Abdominal CT scan. It showed a hypervascular nodule about 1 cm over pancreatic tail during arterial phase (arrow head).

and is difficult to be diagnosed especially in elderly. Here we reported this kind of unusual cases.

Case Report

A 71-year-old Chinese man presented to our clinic because of several episodes of symptomatic hypoglycemia without definite diagnosis in recent years. There were no systemic disorders such as hypertension, diabetes mellitus, or malignancy, except for history of hyperuricemia and smoking. On physical examination, his body weight was 64 kg and height was 168 cm. His fasting plasma glucose was normal (86 mg/dl). The normal liver and renal function tests were disclosed. Hormones analyses by Immulite machine did not reveal adrenal insufficiency (8AM ACTH:

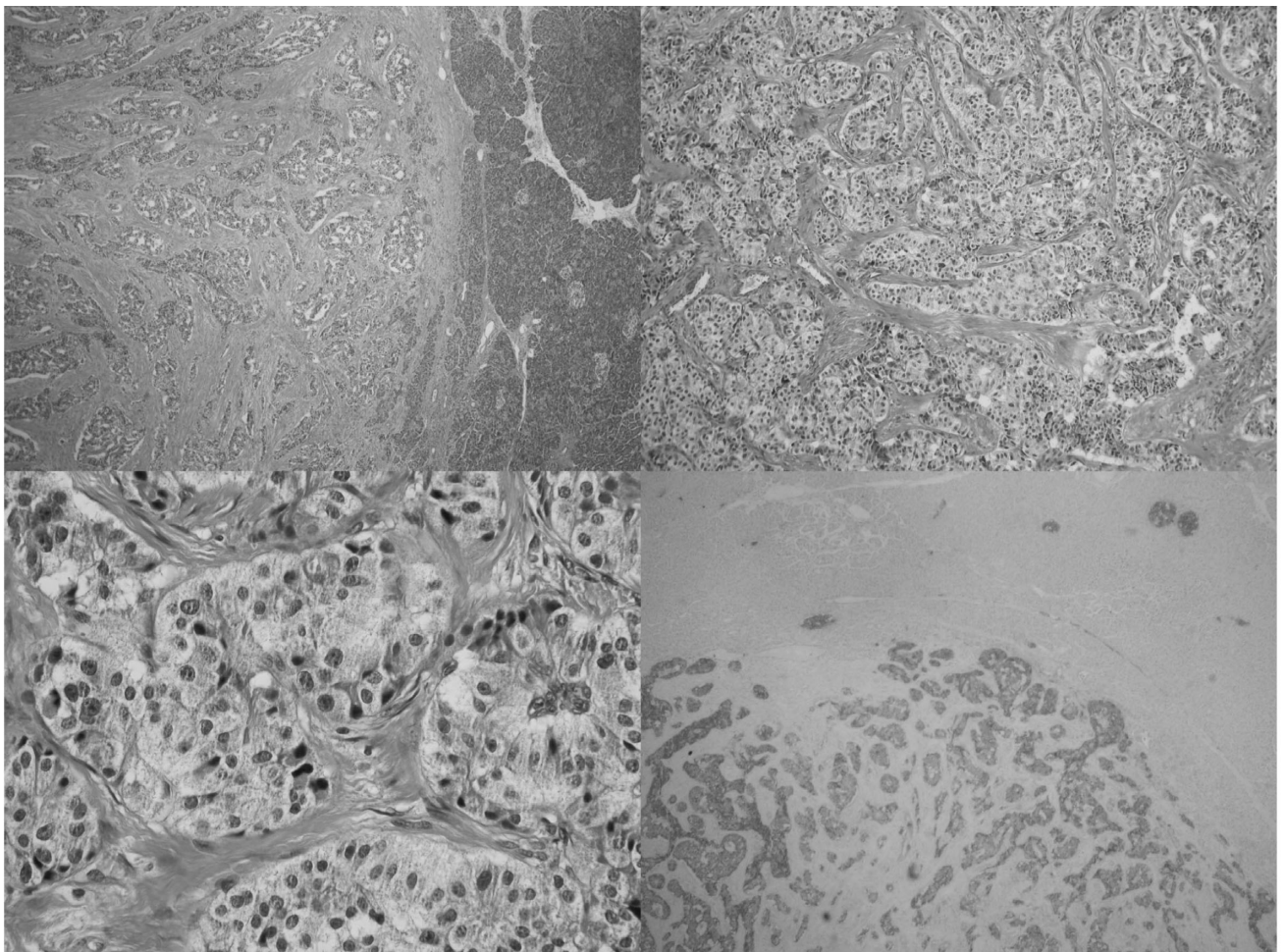


Fig.2. Islet cell tumor. An islet cell tumor composed of hyperchromatic neoplastic cells, arranged in festoons and organoid nests pattern (H & E stain original, X40, X400). The immunostains are positive for chromogranin, synaptophysin and insulin (immunohistochemical stain method--specified for insulin).

21.6 pg/ml, Cortisol: 15.5 μ g/dl) or hypothyroidism (TSH: 2.81 mIU/l, Free T4: 1.03 ng/ml). Prolonged supervised fasting test was performed and symptomatic hypoglycemia occurred after fasting for 10 hours. The simultaneous blood analyses during episodic hypoglycemia showed hypoinsulinemic hypoglycemia as plasma glucose of 38 mg/dl, serum insulin level of 1.0 μ IU/ml (fasting normal range: 0.0-15.6 μ IU/ml by two-site immunoenzymometric assay), and serum C-peptide level of 1.6 ng/ml.

Abdominal computed tomography was performed and it showed a hypervascular nodule of about 1 cm over pancreatic tail during arterial phase (Fig. 1). Because of highly suspected insulinoma, distal pancreatectomy was performed. On operation, the cut surface was smooth with a gray white firm mass. Histologically, it was composed of hyperchromatic neoplastic cells arranged in festoons and organoid nests pattern. The immunostains are positive for chromogranin, synaptophysin and insulin (Fig. 2). The final diagnosis was insulin-secreting islet cell tumor.

He has been free of symptomatic hypoglycemia after surgery.

Discussion

It has been known that insulinoma or islet cell tumor is characterized by spontaneous fasting hypoglycemia and its diagnosis is confirmed by inappropriately high serum insulin levels ($> 6 \mu$ IU/ml) during hypoglycemia (fasting plasma glucose < 45 mg/dl), and/or high insulin/glucose ratio (IGR > 0.30). Biochemical tests are still the mainstay of diagnosis and are based on demonstrating Whipple's triad: 1) hypoglycemic attacks while in the fasting state, 2) blood glucose levels are less than 45 mg/dl during the attacks, and 3) glucose administration relieves the symptoms². But few cases have been reported that did not fulfill the criteria of hyperinsulinemic hypoglycemia typical for insulinoma.

Wiesli et al³. reported that all 11 patients with insulinoma have insulin concentrations more than

6 μ IU/ml during hypoglycemia as measured by radioimmunoassay (RIAs). However, their insulin concentrations were significantly lower when measured by ELISA (enzyme-linked immunosorbent assay) and four patients (4/11) with insulinoma had insulin concentrations less than 6 μ IU/ml during hypoglycemia.

Because insulinoma may secrete other hormones or products in addition to insulin, we must notice their possible pathological effects. Plasma proinsulin and C-peptide levels are known to be elevated in patients with insulinomas, and the proinsulin content in secretory islet-cell tumors is higher than in normal pancreatic tissues. Proinsulin has a hypoglycemic effect, and tumors that secrete predominantly proinsulin have been well documented to cause hypoglycemia. Kao et al⁴. reported that at the end of a prolonged fast, 85% of the insulinoma patients had proinsulin levels greater than the upper limit of normal reference range, compared with 50% for insulin and 20% for C-peptide. In the report by Hirshberg et al., they showed that the proinsulin level has a diagnostic sensitivity for insulinoma of 90% at the start of a fast and 82% at the end of a fast⁵. Thus, it seemed that insulin and proinsulin may play important roles in the pathogenesis of insulinoma as evidenced by hyperinsulinemic hypoglycemia.

Different specific insulin assays have been evaluated in patients with insulinoma. Shimizu et al⁶. reported that insulin concentrations by highly specific assays were markedly 14-93% lower than the values obtained by traditional RIA assays. This may be explained by the 14% cross-reactivity of the traditional RIA with proinsulin, and the traditional RIA is more sensitive compared with specific ELISA in the evaluation of patients with fasting hypoglycemia due to insulinoma with predominate proinsulin secretion⁷.

When applying traditional criteria to this case using the newer, highly specific insulin assay, our patient had severe fasting hypoglycemia but insulin level was appropriately suppressed at or below the published reference range, with plasma glucose as low as

38 mg/dl and insulin as 1.0 μ IU/ml. However, the C-peptide level was borderline or somewhat elevated at 1.6 ng/ml, compared with Service's upper limit in normal during a prolonged fast of 0.6 ng/ml, consistent with the finding of endogenous hyperinsulinism. Recently, Vezzosi et al.⁸ studied the respective value of insulin, C-peptide and proinsulin levels in 33 patients with endogenous hyperinsulinism and in 67 controls to determine the best parameters and thresholds to make or to rule out the diagnosis of endogenous hyperinsulinism. The conclusions showed that proinsulin levels above 5 pmol/l with blood glucose levels below 45 mg/dl (2.5 mmol/l) during a 72-hour fast test represent the best criterion for the diagnosis of endogenous hyperinsulinism, reaching 100% diagnostic specificity and sensitivity. Concomitant C-peptide levels above 0.53 ng/ml (0.2 nmol/l) also make the diagnosis of all the insulinoma patients, while insulin levels have much less diagnostic accuracy. In our case, consistent with this study findings, C-peptide was above 0.53 ng/ml (1.6 ng/ml) without hyperinsulinemia when blood glucose levels below 45 mg/dl (38 mg/dl). The limitation in our case is that proinsulin and serum β -hydroxybutyrate concentrations are not available. The β -hydroxybutyrate should be undetectable in situation of hyperinsulinemic hypoglycemia and it is another laboratory data assisted in diagnosis of suspected insulinoma. Another limitation is that we did not perform splenic vein sampling with intravenous calcium infusion method. It may further directly confirm real hypoinsulinemia. The highly pulsatile insulin secretion pattern may possibly underdetect the insulin concentrations. Therefore, a true hypoinsulinemic hypoglycemia is probably an erroneous term.

The diagnosis of insulinoma or islet cell tumor can't be excluded by hypoinsulinemic hypoglycemia solely by highly specific insulin assays, such as ELISA (reporting a cross-reactivity of only less than 0.2% with proinsulin). Other analytic methods for cross-reacting insulin by conventional nonspecific

insulin radioimmunoassays (RIA), as polyclonal antibodies that can cross react with proinsulin may be indicated when insulinoma is highly suspected or pancreatic nodule is found by tomography in situation of fasting hypoglycemia. However, it should be considered in a few rare conditions, such as coexisting insulin-like growth factor or insulin antibodies.

In conclusion, insulin concentrations may be lower in patients with insulinoma when measured by highly specific immunoassays than by RIA, that exhibiting considerable cross-reactivity with proinsulin. Thus, hyperinsulinemia must be considered if insulin concentrations are not diagnostic for insulinoma during hypoglycemia measured by highly specific assays, such as ELISA. Using more cross-reactivity for proinsulin nonspecific insulin assay (RIA) or assays specific for proinsulin may be helpful in the setting of fasting hypoglycemia, because of no single criterion for hyperinsulinemia is 100% sensitivity and 100% specific in the diagnostic evaluation of insulinoma patients at present.

References

1. Service FJ. Hypoglycemic disorders. *N Engl J Med* 1995; 332: 1144-52.
2. Whipple AO, Frantz VK. Adenoma of the islet cell with hyperinsulinemia. *Ann Surg* 1985; 101: 1299-304.
3. Wiesli P, Brandle M, Zapf J, et al. Assessment of hyperinsulinemia at the termination of the prolonged fast. *Clin Chim Acta* 2004; 342: 227-31.
4. Kao PC, Taylor RL, Service FJ. Proinsulin by immunochemiluminometric assay for the diagnosis of insulinoma. *J Clin Endocrinol Metab* 1994; 78: 1048-51.
5. Hirshberg B, Livi A, Bartlett DL, et al. Forty-eight-hour fast: the diagnostic test for insulinoma. *J Clin Endocrinol Metab* 2000; 85: 3222-6.
6. Shimizu T, Sasakuma F, Ishikawa O, et al. Assessment of immunoassays for insulin in diagnostic tests for insulinoma. *Diabetes Res Clin Pract* 1994; 26: 149-54.
7. Chia CW, Saudek CD. The diagnosis of fasting hypoglycemia due to an islet-cell tumor obscured by a highly specific insulin assay. *J Clin Endocrinol Metab* 2003; 88: 1464-67.
8. D Vezzosi, A Bennet, J Fauvel, et al. Insulin, C-peptide and proinsulin for the biochemical diagnosis of hypoglycaemia related to endogenous hyperinsulinism. *Eur J Endocrinol* 2007; 157(1): 75-83.

以低血糖低胰島素血症為表現的胰島細胞腫瘤 —病例報告

盧介祥¹ 花士哲¹ 吳崇榮^{2,3}

¹嘉義基督教醫院 內科部新陳代謝科

²嘉義榮民醫院 新陳代謝科

³南華大學 自然醫學研究所

摘 要

我們報告一個罕見病例，一位有胰島細胞腫瘤的老年人，實驗室檢驗診斷為低血糖低胰島素血症。胰島細胞腫瘤的臨床表現特點為反覆自發性的空腹低血糖，而診斷上是依據發生低血糖時同時有不正常偏高的胰島素值或是偏高的胰島素對血糖的比值。這篇報告說明單依靠低血糖低胰島素血症不能絕對排除胰島細胞腫瘤的診斷可能性。在高度懷疑罹患胰島細胞腫瘤的病人，卻出現低血糖低胰島素血症，當其低血糖時，除了測定血中胰島素濃度之外，應考慮進一步分析測定有交互反應的胰島素或前胰島素或類胰島素生長因子濃度。