

Giant Gastric Phytobezoar Successfully Eradicated by Oral Intake Plus Endoscopic Injection of Coca-Cola : A Case Report

Fu-Chih Hung¹, Chi-Yu Cho², Ching-Chu Lo¹, and Jow-Jyh Hwang¹

¹*Division of Hepatogastroenterology, Department of Internal Medicine, and*

²*Division of Pathology, St. Martin De Porres Hospital*

Abstract

A phytobezoar is composed of indigestible fruit and vegetable fibers. Nonsurgical treatment had been reported for phytobezoar. Surgical intervention is considered necessary in cases with huge and impacted gastric phytobezoars. We report our experience in fragmenting a giant and solid phytobezoar using Coca-Cola solution intake per oral plus endoscopic injection. A 76-year-old man with a history of massive bleeding secondary to gastric ulcer underwent pyloroplasty without vagotomy. He was admitted because of postprandial colicky epigastric pain for 2 months. Upper gastrointestinal endoscopy showed a giant, blackish, solid bezoar with smooth-shiny surface occupying almost two third of lumen of stomach. The patient was given two cans of Coca-Cola every 6 hours for a total 4 days of treatment. Endoscopy two days after treatment, the bezoar was partially dissolved and softened. We broke the residual phytobezoar by one coin forcep with concomitant endoscopic injection of Coca-Cola solution into the phytobezoar. We repeated endoscopic injection of the Coca-Cola solution into these smaller bezoars. Follow-up endoscopy four days later showed disappearance of these bezoars except an ulcer at gastric angularis. There was no evidence of intestinal obstruction found in neither the small bowel nor the lower gastrointestinal series. We therefore conclude that this could be a safe and effective alternative method that can be performed in a medical ward thus avoiding possible surgery especially to these high-risk patients. (J Intern Med Taiwan 2009; 20: 162-166)

Key Words : Phytobezoar, Endoscopic injection, Coca-Cola, Coin forcep

Introduction

Bezoars are concretions in the digestive tract composing of different swallowed substances that have stagnated. Most bezoars are in the stomach, but they may be encountered elsewhere in the whole gastrointestinal tract¹. The most frequent are phytobezoars composed of indigestible fruits and vegetables fibers and trichobezoars made of hair.

Other rare bezoars include pharmacobezoars, lactobezoars and foreign body bezoars, etc. Gastric bezoars, especially those of the phytobezoar type are a relatively uncommon late complication of previous gastroduodenal surgery, with a reported incidence of 0.4%² that have resulted in impaired gastric emptying even gastroparesis³ and/or decreased acid production (55.9-61.1%)⁴. The

Correspondence and requests for reprints : Dr. Ching-Chu Lo

Address : Division of Hepatogastroenterology, Department of Internal Medicine, St. Martin De Porres Hospital No. 565, Sec. 2, Daya Rd., Chiayi City, Taiwan

diagnosis should be suspected with the clinical and barium study findings, and confirmed by computerized tomography and endoscopy. When the bezoars produce symptoms, removal is always necessary. Many approaches have been proposed for the treatment of bezoars, such as gastroscopic fragmentation, nasogastric lavage or suction, and enzymatic therapy. Different endoscopic methods have also been reported including water jet, forceps, snare, and basket^{5,6} We present herein a 76-year-old man who had a giant gastric phytobezoar that was successfully eradicated by oral intake plus endoscopic injection of Coca-Cola solution and fragmentation by one coin forcep thus avoiding surgery.

Case report

A 76-year-old man with the medical disease of benign prostatic hyperplasia was admitted to our gastrointestinal ward because of postprandial colicky epigastric pain for 2 months duration but more exacerbated in the most recent one week. He had a history of gastric ulcer complicated with massive bleeding and underwent pyloroplasty without vagotomy for the past 20 years. The abdomen was soft without distension. There was tenderness over epigastric area with an old midline laparotomy scar on physical examination. Upper gastrointestinal endoscopy (GIF-XQ240, Olympus, Japan) was performed under the clinical suspicion of peptic ulcer disease but showed a giant, blackish and solid bezoar with smooth, shiny surface occupying nearly two third of gastric lumen (Fig. 1.A). Phytobezoar was confirmed pathologically since it contained markedly congested and necrotic vegetable-like materials (Fig. 2). We tried to break the phytobezoar with a Dormia basket (Wilson-Cook medical MSB-3X6) but in vain. We decided to treat the patient by drinking two cans (710 ml) of Coca-Cola (Coca-Cola Co., Kaohsiung, Taiwan) every 6 hours. Two days later, repeat endoscopy

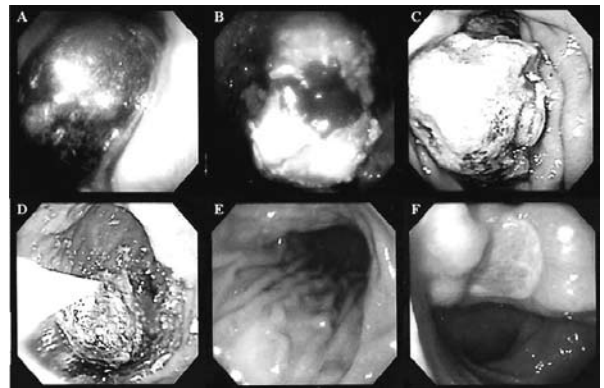


Fig.1. A. Upper endoscopic views of the giant, blackish and solid phytobezoar with smooth-shiny surface filled nearly two third of gastric stomach.

B. Two days later, after the patient had drunk two cans (710 ml) of Coca-Cola every 6 hours, the second endoscopy demonstrated that the phytobezoar was partially dissolved and softened.

C. The coin forcep was used to break the phytobezoar and then the Coca-Cola solution was injected into the giant phytobezoar by a disposable injector and the giant phytobezoar was broken into three smaller pieces.

D. Coca-Cola solution was used for further injections into the three fragmented smaller bezoars respectively.

E. At the third endoscopy on the fourth day, these bezoars have all disappeared.

F. An active giant compressive ulcer at gastric angularis secondary to the original gastric phytobezoar was found after all fragmented bezoars were cleared.

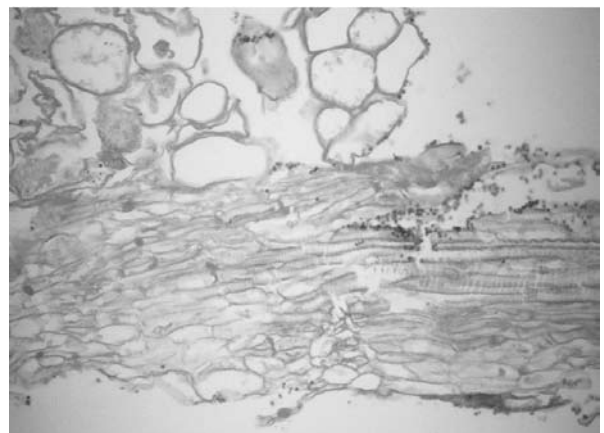


Fig.2. The microscopic findings of the gastric bezoar show markedly congested and necrotic vegetable-like materials (H&E stain, 100X).

demonstrated the gastric phytobezoar was partially dissolved and softened (Fig. 1.B). The coin forcep (Shark Tooth FG-32L-1, Olympus, Japan) was used to fragment the phytobezoar and then the Coca-Cola solution with total 60 ml was injected to the giant gastric phytobezoar by an injection needle^{7,8}. The phytobezoar was broken into three smaller pieces (Fig. 1.C). The Coca-Cola solution was used for further injection into the three fragmented bezoars (Fig. 1.D) and the procedure required 20 minutes without complication. At endoscopy on the fourth day of this hospitalization, these bezoars had disappeared (Fig. 1.E) and a giant ulcer was found on the gastric angularis (Fig. 1.F). This could probably be secondary to the long-term compressive pressure from the giant gastric phytobezoar. The patient continued to drink 12 liters of Coca-Cola solution for the whole 4 days of treatment until those bezoars had cleared. Follow-up small bowel and lower gastrointestinal series showed no evidence of intestinal obstruction by the dissolved bezoars. There were no procedure-related complications throughout the whole course of treatment.

Discussion

Bezoars are rarely symptomatic; however, the clinical symptoms vary depending upon the location of bezoars if they existed. The clinical manifestations vary from no symptoms to acute abdominal syndrome. Gastric bezoars should be considered after laparoscopic adjustable gastric banding if the patients complain of persistent high fullness and vomiting^{9,11}. The endoscopy still remains the best choice for non-invasive diagnostic technique¹².

There is no standard method for the evacuation of gastric phytobezoars. Soft phytobezoars occurring in the postoperative stomach may be readily removed by enzyme digestion and manipulation^{13,14}. However care should be taken since chronic irritation of the gastric antral mucosa

could lead to ulceration and formation of hyperplastic polyps¹⁵. Small gastric bezoars should be conservatively treated initially by non-surgical methods such as laser, prokinetic and enzymatic dissolutions including papain, cellulase, acetylcysteine and Coca-Cola or mechanical disruption such as gastric lavage, endoscopic fragmentation¹⁶ or extracorporeal lithotripsy¹⁷. The treatment of phytobezoars is sometimes difficult because they are occasionally giant-sized and may clinically mimic an intra-abdominal mass and induced complications including intestinal obstruction, perforation, pancreatitis, appendicitis, pneumatosis intestinalis or intussusception¹⁸. Surgery is only recommended in cases with massive or large gastric bezoars, that impacted or complicated cases presenting with perforation, penetration or obstruction¹⁹.

The real mechanism of Coca-Cola dissolution is not well understood at present. The hypothetical mechanism of Coca-Cola dissolution could be NaHCO₃ content contained in Coca-Cola has a mucolytic effect²⁰ or CO₂ bubbles associated with the acidity of Coca-Cola that penetrates of CO₂ bubbles into the surface of bezoars may digest the fibers of concretion. The combined action of NaHCO₃ and CO₂ as well as unknown agents in Coca Cola are considered the important factors in dissolving bezoars²¹. However the differences of efficacy between simple Coca-Cola lavage and combination of endoscopic intrabezoar injection plus oral intake of Coca-Cola was not clearly defined, although the combination method seemed to be more effective^{7,8}. A prospective randomized control trial study is needed to clarify.

Large gastric phytobezoars, when uncomplicated, endoscopic or surgical removal can be applied easily. Endoscopic removals of the large gastric phytobezoars in patients with gastric dysmotility disorders usually are difficult without gradual fragmentation. The instruments of

endoscopic fragmentation include water jets, forceps, snares, lithotripters or baskets. Those factors affect the choice of endoscopic treatment methods include (1) composition of the bezoars (2) the size of gastric bezoars (3) associated complications existed especially for persimmon bezoars (4) the experience or preference of the clinicians. Treatment of these lesions by endoscopy consists in direct removal of the bezoar if the size of bezoar is < 3 cm in diameter. Endoscopic fragmentation is needed if size of bezoar ≥ 3 cm, followed by extraction of fragments to prevent the risk of intestinal obstruction. Surgical removal by gastrotomy has been performed. With the advent of laparoscopic surgery, it became possible to remove such lesions without large abdominal incisions.

The recurrence rate of gastric bezoars has been reported to 14%²². To prevent bezoars reformation these patients should avoid or minimize intake of particular fibers in their diet especially persimmon fruits composing of high concentrations of tannin, usually citrus and vegetable fibers, avoiding stringy vegetables, chewing food thoroughly, prokinetics including, metoclopramide or erythromycin for patient known with gastrointestinal tract dysmotility and behavioral therapy plus selective serotonin receptor inhibitor or tricyclic antidepressants treatment for trichotillomania vegetable fibers²³.

We suggest that patients with small gastric bezoars should be conservatively treated initially by non-surgical methods such as laser, prokinetics and enzymatic dissolutions or mechanical disruption. Bigger gastric phytobezoars may be treated by endoscopic removal after Coca-Cola solution oral intake plus endoscopic injection and the concomitant fragmentation using coin forceps. Surgery is only recommended in cases with huge, massive, impacted or complicated cases presenting with perforation, penetration or obstruction.

References

- Zamir D, Goldblum C, Linova L, Polychuck I, Reitblat T, Yoffe B. Phytobezoars and trichobezoars: a 10-year experience. *J Clin Gastroenterol* 2004; 38: 873-6.
- Silva FG, Goncalves C, Vasconcelos H, Cotrim I. Endoscopic and enzymatic treatment of gastric bezoar with acetylcysteine. *Endoscopy* 2002; 34: 845.
- Feigenbaum K. Update on gastroparesis. *Gastroenterol Nurs* 2006; 29: 239-44; quiz 245-6.
- Erzurumlu K, Malazgirt Z, Bektas A, et al. Gastrointestinal bezoars: a retrospective analysis of 34 cases. *World J Gastroenterol* 2005; 11: 1813-7.
- Rider JA, Foresti-Lorente RF, Garrido J, et al. Gastric bezoars: treatment and prevention. *Am J Gastroenterol* 1984; 79: 357-9.
- Wang YG, Seitz U, Li ZL, Soehendra N, Qiao XA. Endoscopic management of huge bezoars. *Endoscopy* 1998; 30: 371-4.
- Chung YW, Han DS, Park YK, et al. Huge gastric diospyrobezoars successfully treated by oral intake and endoscopic injection of Coca-Cola. *Dig Liver Dis* 2006; 38: 515-7.
- Sechopoulos P, Robotis JF, Rokkas T. Gastric bezoar treated endoscopically with a carbonated beverage: case report. *Gastrointest Endosc* 2004; 60: 662-4.
- Veronelli A, Ranieri R, Laneri M, et al. Gastric bezoars after adjustable gastric banding. *Obes Surg* 2004; 14: 796-7.
- Parameswaran R, Ferrando J, Sigurdsson A. Gastric bezoar complicating laparoscopic adjustable gastric banding with band slippage. *Obes Surg* 2006; 16: 1683-4.
- Pinto D, Carrodegua L, Soto F, et al. Gastric bezoar after laparoscopic Roux-en-Y gastric bypass. *Obes Surg* 2006; 16: 365-8.
- Ladas SD, Triantafyllou K, Tzathas C, Tassios P, Rokkas T, Raptis SA. Gastric phytobezoars may be treated by nasogastric Coca-Cola lavage. *Eur J Gastroenterol Hepatol* 2002; 14: 801-3.
- Walker-Renard P. Update on the medicinal management of phytobezoars. *Am J Gastroenterol* 1993; 88: 1663-6.
- Baker EL, Baker WL, Cloney DJ. Resolution of a phytobezoar with Aldoph's Meat Tenderizer. *Pharmacotherapy* 2007; 27: 299-302.
- Misra SP, Dwivedi M, Misra V. Endoscopic management of a new entity-plastobezoar: a case report and review of literature. *World J Gastroenterol* 2006; 12: 6730-3.
- Bruzzese A, Chiarini S, Marchegiani C, Corbellini L, Stella S. [Endoscopic fragmentation of gastric phytobezoars as a valid alternative, in selected cases, to traditional surgery]. *G Chir* 1997; 18: 485-7.
- Kuo JY, Mo LR, Tsai CC, Chou CY, Lin RC, Chang KK. Nonoperative treatment of gastric bezoars using electrohydraulic lithotripsy. *Endoscopy* 1999; 31: 386-8.
- Baskonus I, Gokalp A, Maralcan G, Sanal I. Giant gastric trichobezoar. *Int J Clin Pract* 2002; 56: 399-400.

19. Sciume C, Geraci G, Pisello F, et al. [Gastric foreign body: bezoars. Apropos of two cases]. *Ann Ital Chir* 2004; 75: 479-82.
20. Kato H, Nakamura M, Orito E, Ueda R, Mizokami M. The first report of successful nasogastric Coca-Cola lavage treatment for bitter persimmon phytobezoars in Japan. *Am J Gastroenterol* 2003; 98: 1662-3.
21. Lin CS, Tung CF, Peng YC, Chow WK, Chang CS, Hu WH. Successful treatment with a combination of endoscopic injection and irrigation with coca cola for gastric bezoar-induced gastric outlet obstruction. *J Chin Med Assoc* 2008; 71: 49-52.
22. Hall JD, Shami VM. Rapunzel's syndrome: gastric bezoars and endoscopic management. *Gastrointest Endosc Clin N Am* 2006; 16: 111-9.
23. Pitiakoudis M, Tsaroucha A, Mimidis K, et al. Esophageal and small bowel obstruction by occupational bezoar: report of a case. *BMC Gastroenterol* 2003; 3: 13.

利用口服加上內視鏡注射可口可樂成功 移除巨大胃植物糞石：一病例報告

洪福枝¹ 卓啓裕² 羅清池¹ 黃國智¹

財團法人天主教聖馬爾定醫院 ¹內科部腸胃肝膽科 ²病理科

摘 要

胃植物糞石是由未消化的水果及蔬菜纖維所組成。雖然文獻上有胃植物糞石的非手術治療報告，但是巨大並且造成腸胃道阻塞的胃植物糞石，手術通常被認為是必要的處置。我們報告一例利用口服加上內視鏡注射可口可樂溶液成功碎裂並且移除巨大且硬實之胃植物糞石的治療經驗。76歲男性病患有大量胃潰瘍出血接受胃幽門整形手術但沒有切除迷走神經的病史，抱怨最近兩個月來餐後上腹部絞痛。上消化道內視鏡檢查發現一黑色發亮、巨大且硬實之胃糞石佔據將近三分之二胃空腔。我們請病患每六小時口服2瓶罐裝可口可樂溶液，持續至四天治療期結束總共服用12公升。住院兩天後內視鏡檢查發現胃糞石已經軟化且部份溶解，此時我們利用硬幣夾初步破壞殘餘的胃糞石並同時在內視鏡直視下注射可口可樂溶液進入部份溶解的胃糞石中，此巨大胃糞石立即碎裂成三塊；接著分別注射可口可樂溶液至這三塊碎裂後的胃糞石中。住院四天後內視鏡檢查發現除了有一胃角潰瘍外，這些胃糞石已經完全消失。其後安排上消化道以及下消化道攝影排除了可能因碎裂的胃糞石所併發的腸胃道阻塞。我們因此認為這種治療方式，尤其針對那些高醫療風險的病人，可能是一種既安全快速且有效而可選擇的治療方式並且可以在內科病房執行，避免掉不必要的手術。