

Isolated Intraluminal Gallbladder Hemorrhage After Anticoagulation Therapy : Report of A Case

Hsien-Ping Lin, and Yu-Chiang Lin¹

*Division of Gastroenterology, Department of Internal Medicine,
Jen-Ai Hospital, Taichung, Taiwan*

*¹Department of General Surgery,
China Medical University Hospital, Taichung, Taiwan*

Abstract

The gallbladder hemorrhage is a rare disease. Some reported cases were associated with cholecystitis, trauma, neoplasm, hemophilia or cystic artery aneurysm. Anticoagulation therapy caused some complications due to bleeding tendency. But gallbladder hemorrhage after anticoagulation therapy was rarely reported. We reported a case with gallbladder hemorrhage after anticoagulation therapy. This was an 80 year-old male patient who had anticoagulant - warfarin, for cerebral infarction. He was found to have a gallbladder tumor during routine abdominal ultrasonography for chronic hepatitis B. He underwent laparoscopic cholecystectomy and intraluminal hemorrhage of gallbladder was discovered. We suggested that the patient had gallbladder hemorrhage due to the complication of anticoagulation therapy. We concluded that gallbladder hemorrhage should be included in the differential diagnosis of patients with a gallbladder tumor. (J Intern Med Taiwan 2010; 21: 62-65)

Key Words : Intraluminal gallbladder hemorrhage, Anticoagulation therapy

Introduction

Though biliary tract bleeding, hemobilia, is not so rare clinically, gallbladder hemorrhage is rare. Some reported cases were associated with cholecystitis, trauma, neoplasm, hemophilia or cystic artery aneurysm¹⁻⁷. Anticoagulation therapy might cause some bleeding complications, and some sporadic cases of intra-abdominal hematoma due to anticoagulation therapy were reported^{8,9}. However, gallbladder hemorrhage due to anticoagulation therapy was rarely reported.

Case Report

This is an 80-year-old male patient who underwent routine abdominal ultrasonography for chronic hepatitis B. An intraluminal amorphous heterogeneous tumor was noted in the gallbladder (Fig. 1). He had no specific complaint about this finding. Reviewing his medical history, he had an episode of cerebral infarct with mild aphasia 4 months ago. He had had warfarin treatment, 2.5 mg/d, since then. He had a prolonged prothrombin time (PT) one month ago during follow-up. It

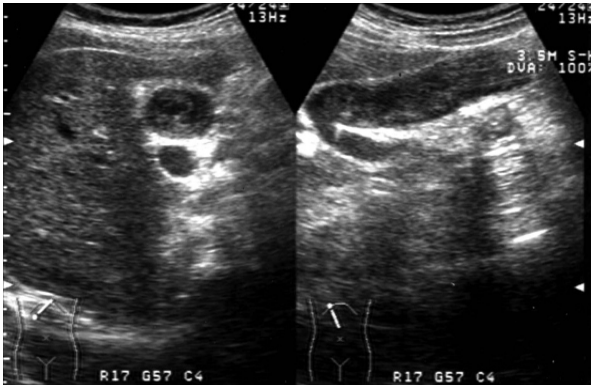


Fig.1 The abdominal ultrasonography showing an amorphous heterogeneous mass in cross and longitudinal sections of the gallbladder.

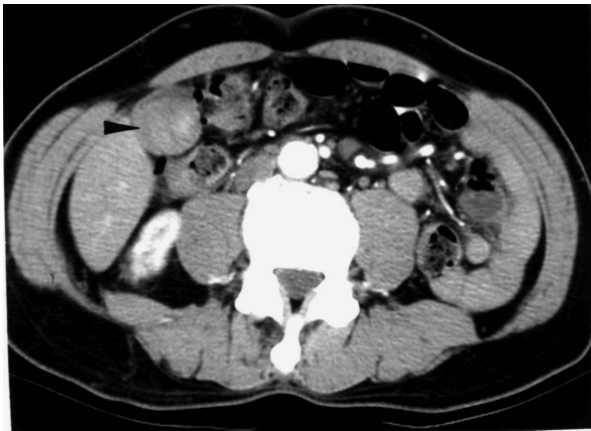

Fig.2 Computed tomography showing a non-enhanced tumor-like lesion (arrowhead) in the gallbladder after contrast enhancement.

was 158.5 seconds (control 12.5 seconds), and the INR was 13.29. After stopping warfarin, PT returned to 13.5 seconds (control 13 seconds) one week before this ultrasonography. He had no specific symptom or sign related to bleeding tendency during this period. He had no petechia or ecchymoses in appearance. He had no abdominal pain or tenderness. No jaundice or anemia was seen. The blood cell counts and biochemistry tests were within normal limits. The CEA level was under normal limit. He underwent abdominal computed tomography, a high-attenuated gallbladder tumor without enhancement was noted (Fig. 2). Because gallbladder neoplasm could not be excluded,

he underwent laparoscopic cholecystectomy. Upon opening the gallbladder postoperatively, only some old blood clots were discovered in it. Microscopically, it shows a picture of chronic cholecystitis of gallbladder with mild chronic inflammatory cells infiltrating in lamina propria.

The postoperative course was uneventful. We suggested that this was a case of intraluminal hemorrhage of gallbladder complicated by anticoagulation therapy.

Discussion

Isolated intraluminal gallbladder hemorrhage is usually associated with cholecystitis, trauma, neoplasm, hemophilia or cystic artery aneurysm¹⁻⁷. As increasing prevalence of radiofrequency ablation for liver tumors, the reports of the complication of gallbladder hemorrhage are increasing recently¹⁰. Bleeding tendency and related complications are not uncommon during anticoagulation therapy. Anticoagulation therapy might have some bleeding complications, and some sporadic cases of intra-abdominal hematoma due to anticoagulation therapy were reported^{8,9}. However, isolated gallbladder hemorrhage due to anticoagulation therapy was rarely reported, only one case reported in the French literature. This case had no trauma history or congenital bleeding diathesis. He had no history of acute cholecystitis and had no abdominal pain when diagnosed. He had anticoagulation therapy for minor stroke. He had once of overt prolongation of PT during follow-up. Though he had no specific complaint at that time, the gallbladder hemorrhage was detected a few weeks later. So we suggested that the gallbladder hemorrhage was a complication of anticoagulation therapy.

Gallbladder hemorrhage might have the presentations of right upper quadrant abdominal pain, jaundice, fever, upper gastrointestinal bleeding, or hypovolemic shock depends on its etiology¹⁻⁷. The case we reported had no specific

symptom or sign. Reviewing the literature and in our case, gallbladder hemorrhage occurred in bleeding diathesis patients tended to be asymptomatic⁵. The characteristic ultrasonographic finding of gallbladder hemorrhage is a mobile intraluminal echogenic mass caused by blood clots³. It might gravitate when changing patient's position. It should be differentiated with gallbladder neoplasm, biliary sludge and gangrenous cholecystitis. Usually, it is not difficult to make a differential diagnosis from the clinical presentations. Magnetic resonance imaging is better than ultrasonography and computed tomography in differentiation of these lesions. The blood clots are similar to muscles in signal on T1-weighted images, with conversion to hypointensity on T2-weighted images⁴. In our case, the ultrasonographic pictures may present a later stage of gallbladder hemorrhage. The blood clots seemed liquefying, making it amorphous in longitudinal section. Actually, as the hemorrhage evolves, it might present as a cystic lesion in the gallbladder¹¹.

An asymptomatic or uncomplicated isolated intraluminal gallbladder hemorrhage should be treated conservatively^{4,12}. This patient underwent cholecystectomy was due to unawareness of the rare disease of gallbladder hemorrhage. When asymptomatic gallbladder hemorrhage is highly suspected, follows up by abdominal ultrasonography might reduce the unnecessary surgery.

In conclusion, in a patient with anticoagulation therapy, the gallbladder hemorrhage should be included in differential diagnosis of the gallbladder tumors.

References

1. Scharling ES, Geisinger KR. Case of the day. Hemobilia: intraluminal gallbladder hematoma. *J Ultrasound Med* 1993; 12: 244-5.
2. Grant EG, Smirniotopoulos JG. Intraluminal gallbladder hematoma: sonographic evidence of hemobilia. *J Clin Ultrasound* 1983; 11: 507-9.
3. Berland LL, Doust BD, Foley WD. Acute hemorrhage into the gallbladder diagnosed by computed tomography and ultrasonography. *J Comput Assist Tomogr* 1980; 4: 260-2.
4. Kauzlaric D, Barmeir E. Sonography of intraluminal gallbladder hematoma. *J Clin Ultrasound* 1985; 13: 291-4.
5. Shimura T, Kojima T, Tsutsumi S, et al. Gallbladder hematoma in a patient with hemophilia B, report of a case. *Hepatogastroenterology* 2000; 47: 939-41.
6. Levinson JD, Olsen G, Terman JW, et al. Hemobilia secondary to percutaneous liver biopsy. *Arch Intern Med* 1972; 130: 396-400.
7. Pilling DW. Haematoma of the wall of the gall-bladder. *Br J Radiol* 1979; 52: 840-1.
8. DE Brito P, Gomez MA, Besson M, et al. Mesenteric hematoma: unusual complication of a long term oral anticoagulation therapy. *Ann Chir* 2006; 131: 529-32.
9. Behranwala KA, Tisdall M, Habib NH, et al. Spontaneous bilobar subcapsular hematoma of the liver while undergoing anticoagulation therapy: our experience and review of the literature. *Int Surg* 2004; 89: 212-6.
10. Akahane M, Koga H, Kato N, et al. Complications of percutaneous radiofrequency ablation for hepatocellular carcinoma: imaging spectrum and management. *Radiographics* 2005; 25: S57-8.
11. Yiu-Chiu VS, Chiu LC, Wedel VJ. Current cases and concepts: acalculous hemorrhagic cholecystitis. *J Comput Tomogr* 1980; 4: 201-6.
12. Tan SW, Lai SK, Ng KW, et al. Intramural gallbladder hematoma mimicking gallbladder neoplasm in a 33-year-old male. *J Chin Med Assoc* 2005; 68: 146-9.

因抗凝血劑治療單獨產生膽囊腔內出血：一病例報告

林賢平 林裕強¹

仁愛醫療財團法人大里仁愛醫院 消化系內科
¹中國醫藥大學附設醫院 一般外科

摘 要

膽囊腔內出血是一種少見的疾病。曾有些因膽囊炎、外傷、膽囊腫瘤、血友病或膽囊動脈瘤所引起的個案報告。而抗凝血劑的治療可能會因有出血傾向，以致造成一些併發症。不過因抗凝血劑治療而單獨產生膽囊腔內出血的併發症則很少被報導。我們報告一位因抗凝血劑治療而導致膽囊腔內出血的病例。這是一位八十歲的老先生因患有腦血管梗塞而服用抗血劑 - warfarin。他因為有慢性B型肝炎而接受腹部超音波及電腦斷層掃描檢查，意外發現膽囊有疑似腫瘤。他接受了腹腔鏡膽囊切除術，結果發現是單獨的膽囊腔內出血。我們推測這是因抗凝血劑治療而產生膽囊腔內出血的併發症。所以我們建議對於使用抗凝血劑治療的患者如果有不明的膽囊腫瘤時，必須把膽囊腔內出血列入鑑別診斷。