

Right Ventricular Outflow Tract (RVOT) Ventricular Tachycardia (VT) in Pregnancy: A Case Report

Ying-Chi Hsu¹, and Ya-Pei Chen²

¹*Department of Internal Medicine,*

²*Division of Critical Care Medicine,*

Changhua Christian Hospital, Changhua, Taiwan, ROC

Abstract

Maternal cardiac ventricular tachycardia (VT) is rare. The mechanism of right ventricular outflow tract (RVOT) VT in pregnancy remains unknown. Antiarrhythmic agents, such as propranolol, metoprolol, digoxin, and quinidine, have been extensively tested during pregnancy and have been proven safe. For the ventricular tachycardia in pregnancy, if hemodynamics is stable and therapy is necessary, β -blockers are the drug of choice. If at any time VT becomes unstable or if there is evidence of fetal distress, cardioversion should be performed immediately. Here, we report a case of a patient with RVOT VT in pregnancy at 30 weeks' gestation and refractory to propranolol. When the patient suffered VT, unstable blood pressure and fetal distress were noted. We performed cardioversion immediately and induced labor as soon as possible. This patient's VT was successfully controlled by verapamil after the delivery. There was no any structure heart disease revealed by the echocardiogram. (J Intern Med Taiwan 2010; 21: 140-143)

Key Words : Pregnancy, Right ventricular outflow tract ventricular tachycardia, Ventricular tachyarrhythmia, β -blockers

Introduction

A rare incidence of maternal cardiac ventricular tachycardia was observed during pregnancy. The in-hospital cardiac arrhythmia rate is 0.17%¹. Ventricular fibrillation (VF)/ventricular tachycardia (VT) occurs with a frequency of 2/100000¹. This report documents a case of a 28-year-old woman in her third trimester with RVOT VT that was refractory to propranolol. She received several rounds

of cardioversion and was symptom free after a successful delivery.

Case Report

A 28-year-old woman at 30 weeks' gestation (G3A2P0) was admitted to the cardiac care unit. The patient denied past medical problems and medications history. She complained of chest tightness and palpitation in the past month. The duration was approximately 10 minutes without

Correspondence and requests for reprints : Dr. Ya-Pei Chen

Address : Division of Critical Care Medicine, Department of Internal Medicine, Changhua Christian Hospital, Changhua, Taiwan, No. 135, St. Nanshou, Changhua City, 500 Taiwan

any precipitating factors, and was resolved spontaneously or after rest. Chest tightness occurred again before admission when she was walking. She was sent to a local clinic where bigeminal ventricular premature beat (VPB) was revealed by electrocardiogram (ECG), and $MgSO_4$ was administered. She denied a family history of cardiac arrhythmia or sudden death. She also denied any experience of palpitation or chest tightness during her previous pregnancy. Her blood pressure and heart beat were 95/50 mm Hg, and 95 beats/min (bpm), respectively, with bigeminal VPB. Physical examination findings were within normal limits. She had only anemia with a hemoglobin level of 10.9 g/dL; electrolytes were in the normal range. ECG (Fig. 1) revealed bigeminal VPB. The echocardiogram showed hypokinesis over the apex with a left ventricular ejection fraction of 54 %; moderate tricuspid regurgitation with right ventricle (RV) dilation and hypokinesis of the RV free wall; moderate mitral regurgitation with left atrium dilation; and mild pulmonary regurgitation, without hypertrophic obstructive cardiomyopathy (HOCM) or abnormal shunt.

Propranolol (10 mg), 1tab three times daily, was initially given. The VT with heart beat of 153 bpm was noted when she felt chest tightness and dyspnea. Her blood pressure decreased to 73/51 mm Hg, with clear consciousness. The fetal heart beat was 141 bpm at that time. The repetitive 12-lead ECG still showed RVOT VT (Fig. 2). Immediate cardioversion was performed with 200 Joules. Normal sinus rhythm (Fig. 3) at a rate of 76 bpm was maintained. Blood pressure returned to 100/63 mm Hg.

Cardioversion was performed for times for treating recurrent RVOT VT. Her consciousness was clear during the entire course. Refractory VT was suspected. The mother received an emergency cesarean section. Amiodarone was prescribed after the cesarean section, and no subsequent VT was

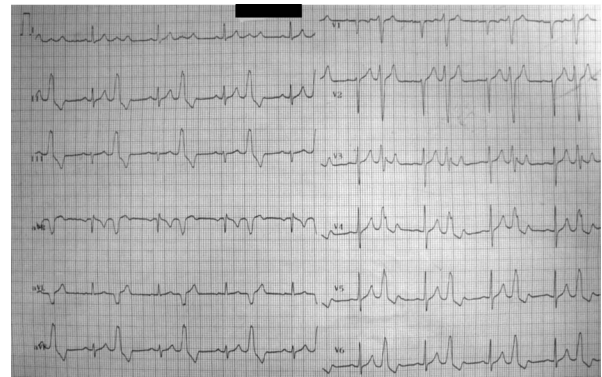


Fig.1. A 12-lead electrocardiogram (ECG) showing bigeminal ventricular premature beat.

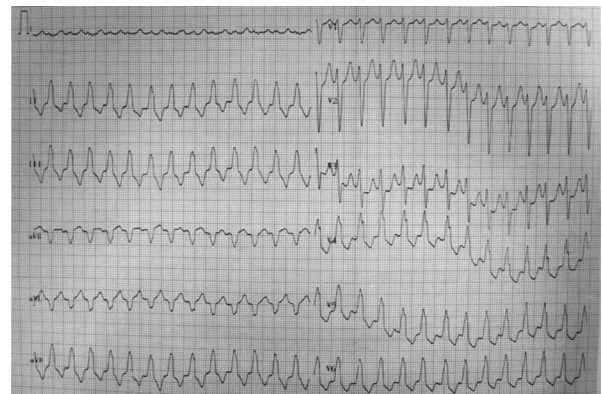


Fig.2. A 12-lead ECG recording of ventricular tachycardia in a 28-year-old pregnant woman.

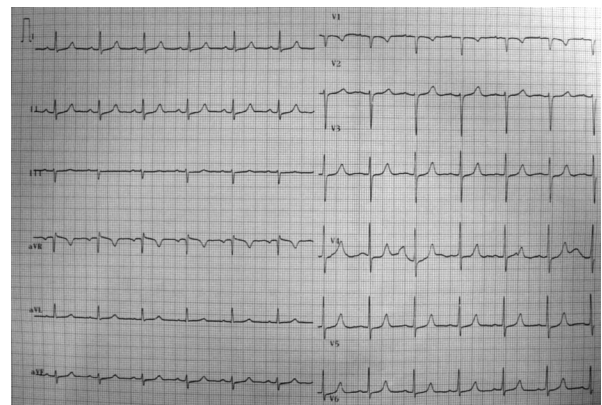


Fig.3. A 12-lead ECG recording of normal sinus rhythm.

noted. The patient was stable and then discharged with a regimen of oral verapamil 40 mg, 1tab three times daily.

Discussion

The RVOT VT in pregnancy is rare. Shotan A

et al² assessed the relationship between symptoms and cardiac arrhythmias in 162 pregnant patients. Isolated atrial premature beats (APBs) was the most common sinus arrhythmias during pregnancy. Isolated VPBs was the most common ventricular arrhythmia. Li JM et al¹ reported a prevalence of 166/100000 for the arrhythmia-associated admission during pregnancy. Sustained VF/VT occurred with a frequency of 2/100000.

RVOT VT is identified on ECG as a left bundle branch block (LBBB) with inferior axis. The mechanism of RVOT VT pathogenesis has not been previously proposed. It is thought to be a cAMP-mediated triggered activity³. Nakagawa M et al⁴ suggests pregnancy-related hormones, various hemodynamic, and autonomic nervous system during pregnancy play important roles in ventricular arrhythmogenesis.

Ventricular tachycardia can be hemodynamically unstable or stable. Management of ventricular tachyarrhythmias is essential to prevent sudden cardiac death of the mother and the fetus. Under stable hemodynamics, the medication to control arrhythmias may be considered. It should be noted that some drugs pass to the fetus, thereby posing a risk of teratogenicity and fetal physiologic alterations. No drug is completely safe. Joglar JA⁵ showed that lidocaine and sotalol US Food and Drug Administration (FDA) class B appear to be relatively safe, despite sotalol being reported to carry a risk of developing polymorphic or torsade de pointes tachycardia⁶. Antiarrhythmic agents, such as propranolol, metoprolol, digoxin, and quinidine, have been extensively tested during pregnancy and have been proven safe⁷. The class III antiarrhythmic agent amiodarone is known for its many and serious side effects for both the mother and the fetus, including hypothyroidism, growth retardation, and premature delivery. Cleary-Goldman J et al⁸ reported that verapamil is effective in pregnant women with right/left ventricular outflow tach-

ycardia. Long-term treatment options for RVOT VT, beta-blockers or verapamil, have a 25% to 50% rate of efficacy⁹. If persistent VT with drug intolerance is noted, the electrophysiologic ablation may be considered.

If at any time VT becomes unstable or if there is evidence of fetal compromise, cardioversion should be delivered immediately and without any risk for mother and children⁶. According to AHA 2005 cardiac arrest associated with pregnancy¹⁰, the best survival rate for infants of more 24 to 25 weeks in gestation occurs when the delivery of the infant occurs no more than 5 minutes after the mother's heart stops beating. Swamy GK et al¹¹ analyzed preterm birth mortality and showed gestational age 22-27 weeks was 53.6% in girls and 52.6% in boys. Preterm birth mortality at a gestational age >27 weeks was quite lower than that at 22-27 weeks. Hence, under unstable hemodynamics without response by cardioversion, if the gestational age <24 weeks, primordial consideration of the mother's safety should be conducted. If the gestational age \geq 24 weeks, the emergency cesarean section may be considered. We initially used propranolol for controlling the VT in our case; however, it seemed refractory to propranolol. VT in pregnancy is an emergency condition for both the mother and the fetus. Our patient had chest tightness and an unstable hemodynamic status. Since the condition was not controlled with drugs, cardioversion followed by an emergency cesarean section was required. Our patient's VT disappeared after delivery. It might be due to the antiarrhythmic effect of amiodarone or the physiological changes after delivery.

In conclusion, the RVOT VT in pregnancy is an emergency condition because of the possibility of mortality for both the mother and the fetus. The mechanism of RVOT VT in pregnancy remains unknown. If it is refractory to drug control, the cardioversion and even emergency cesarean section

for the pregnancy patient may be needed. The prognosis of VT during pregnancy is good in the absence of congenital heart disease⁷.

References

1. Li JM, Nguyen C, Joglar JA, Hamdan MH, Page RL. Frequency and outcome of arrhythmias complicating admission during pregnancy: experience from a high-volume and ethnically-diverse obstetric service. *Clin Cardiol* 2008; 31: 538-41.
2. Shotan A, Ostrzega E, Mehra A, Johnson JV, Elkayam U. Incidence of arrhythmias in normal pregnancy and relation to palpitations, dizziness, and syncope. *Am J Cardiol* 1997; 79: 1061-4.
3. Lerman BB, Stein KM, Markowitz SM, Mittal S, Slotwiner DJ. Ventricular arrhythmias in normal hearts. *Cardiol Clin* 2000; 18: 265-91.
4. Nakagawa M, Katou S, Ichinose M, et al. Characteristics of new-onset ventricular arrhythmias in pregnancy. *J Electrocardiol* 2004; 37: 47-53.
5. Joglar JA, Page RL. Antiarrhythmic drugs in pregnancy. *Curr Opin Cardiol* 2001; 16: 40-5.
6. Trappe HJ. Acute therapy of maternal and fetal arrhythmias during pregnancy. *J Intensive Care Med* 2006; 21: 305-15.
7. Ferrero S, Colombo BM, Ragni N. Maternal arrhythmias during pregnancy. *Arch Gynecol Obstet* 2004; 269: 244-53.
8. Cleary-Goldman J, Salva CR, Infeld JI, Robinson JN. Verapamil-sensitive idiopathic left ventricular tachycardia in pregnancy. *J Matern Fetal Neonatal Med* 2003; 14: 132-5.
9. Srivathsan K, Lester SJ, Appleton CP, Scott LR, Munger TM. Ventricular tachycardia in the absence of structural heart disease. *Indian Pacing Electrophysiol J* 2005; 5: 106-21.
10. 2005 American Heart Association Guidelines for Cardiopulmonary Resuscitation and Emergency Cardiovascular Care: Part 10.8: Cardiac Arrest Associated With Pregnancy. *Circulation* 2005; 112: 150-3.
11. Swamy GK, Østbye T, Skjærven R. Association of preterm birth with long-term survival, reproduction, and next-generation preterm birth. *JAMA* 2008; 299: 1429-36.

懷孕中右心室出口產生的心室頻脈：病例報告

許楹奇¹ 陳雅珮²

財團法人彰化基督教醫院 ¹內科 ²重症醫學科

摘要

懷孕中心臟心室頻脈 (ventricular tachycardia) 是罕見的。由右心室出口產生心室頻脈 (right ventricular outflow tract ventricular tachycardia) 的機制至今尚未明瞭。一些藥物 adenosine、lidocaine、sotalol、propranolol、metoprolol、digoxin 及 quinidine 被證實可以安全的選擇用來治療懷孕婦女的心律不整。對於懷孕中產生心室頻脈，如果血液動力學是穩定而且必需治療時，可以選擇乙型阻斷劑 (β -blockers)；如果心室頻脈使得血行動力學變得不穩定或是如果造成胎兒的危險時，應該立刻執行心臟電擊。我們報告一位懷孕婦女有由右心室出口產生心室頻脈，對於 propranolol 的治療無反應，當時血壓已呈現不穩定現象，胎心音也逐漸下降，在使用心臟電擊後，立即引產。最後這名患者的心室頻脈在生產後成功受到控制。出院後追蹤心臟超音波並未發現有結構性心臟問題。