

Fulminant Leptospirosis: A Case Report and Review of the Literature

Kuan-Jen Su², Yen-Cheng Yeh^{1,2}, and Ren-Jy Ben^{1,2}

¹Division of Infectious Diseases, ²Department of Internal Medicine, Kaohsiung Armed Forces General Hospital

Abstract

Leptospirosis, a zoonotic disease, is usually transmitted from rats to humans through contacting with the contaminated urine. In Taiwan, it especially occurs sporadically after a flood or typhoon. We present a case of flu-like illness contracted by working at a poorly hygienic place where the patient experienced progressive pulmonary-renal syndrome two days after admission. Timely institution of penicillin indicated favorable recovery from severe leptospirosis with good prognosis. (J Intern Med Taiwan 2014; 25: 357-361)

Key Words: Leptospirosis, Weil's disease, Acute pulmonary hemorrhage, Pulmonary-renal syndrome, Microscopic agglutination test (MAT)

Introduction

Leptospirosis is a zoonotic disease usually transmitted from rats to humans through contact with the contaminated urine. It is difficult to diagnose because of the diverse presentations from subclinical flu-like illness to multi-organ failure. Torrential seasonal flooding in areas of high population density is the major risk factor for epidemic severe disease. Military training, outdoor athletic activities, and adventure travel have led to recognized outbreaks and sporadic cases of leptospirosis¹.

Case Report

A previously healthy 55-year-old man came to our emergency department due to fever and sore throat with progressive weakness over lower limbs

for three days. He also had soreness over neck and both arms after heavy loading/lifting for three days. He had been in a tired state for 2 weeks due to overworking in a Chinese soy milk breakfast restaurant that was humid with surface water and poorly hygienic with rodent infestation. On initial examination, his body temperature was 37.5°C, respiratory rate was 19 breaths/min, heart rate was 121 beats/min, and blood pressure was 116/71 mmHg. He was alert and oriented. The skin turgor was senile without rashes or wounds over chest, abdomen or back. His conjunctivae were normal and his sclerae were not icteric. His heart sound and breathing sounds were normal. There was tenderness over neck and soreness over four limbs. The remainder of his physical examinations was unremarkable. The abnormal laboratory investigation showed serum

creatinine of 1.9mg/dL, and C-reactive protein of 28.8 mg/dL.

The chest radiography (Figure 1.) showed borderline cardiomegaly, with no active lung lesion in both lung fields. The cervical spine (C-spine) radiography showed C5 to C7 spondylosis. Under the presumptive diagnosis of C5-spine compression fracture and unknown infection, he was admitted for further evaluation and management.

On hospital day 1, the Magnetic Resonance Imaging (MRI) of C-spine showed bulging discs over C3-4, C4-5, C5-6 posterior central areas with spurting formation which causing cord indentation. The remainder was unremarkable. However, the patient experienced high fever (39°C) with sore throat and there was no tonsillitis except for pharyngeal erythema. A rapid test of a specimen from a nasopharyngeal swab was negative for influenza A and B antigen. The urinalysis was unremarkable. Acetaminophen and cefazolin were administered.

Four hours later, epigastric pain with mild muscle guarding as well as vomiting with coffee grounds material were noted. Abdominal computed tomography was performed and this excluded intra-abdominal lesions.

On hospital day 2 at midnight, the patient experienced progressive respiratory distress associated with confused consciousness and hemoptysis. The chest radiography showed generalized interstitial infiltrations in both lungs (Figure 2). The abnormal laboratory investigation showed hemoglobin: 9.2g/dL, platelets count: $8.1 \times 10^3/\mu\text{L}$, glutamate oxaloacetate transaminase (GOT): 138U/L, glutamate pyruvate transaminase (GPT): 61U/L, total bilirubin: 4.1mg/dL and the serum creatinine was 2.6 mg/dL. Acute pulmonary hemorrhage with respiratory failure was considered. The patient was transferred to the intensive care unit where he received endotracheal intubation with mechanical ventilation. Meanwhile, the bronchoscopy revealed

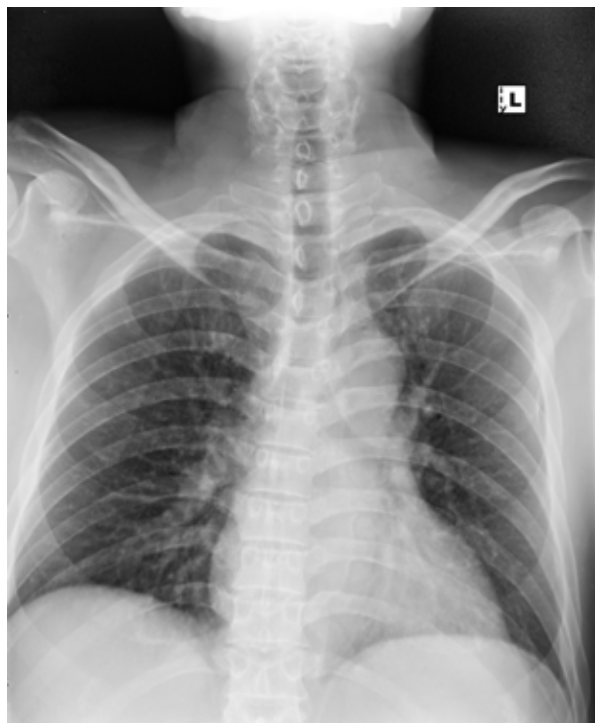


Figure 1. Chest radiograph on admission showing borderline cardiomegaly, no active lung lesion in both lung fields.

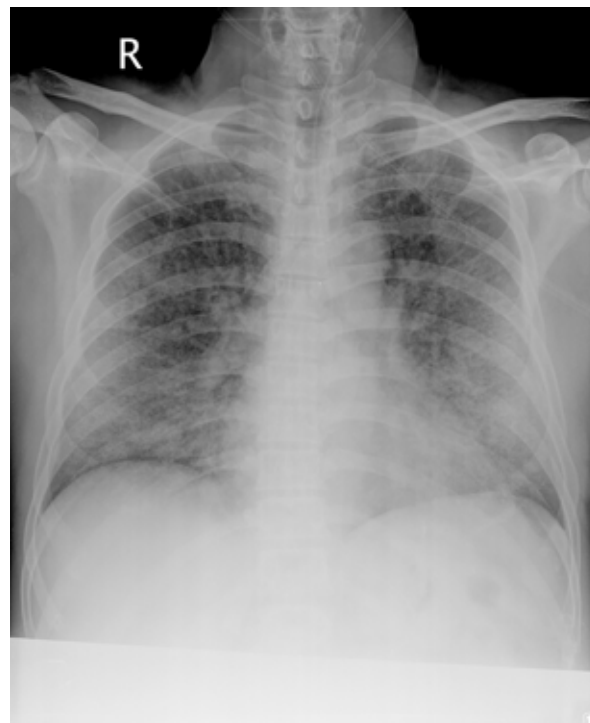

Figure 2. Chest radiograph showed generalized interstitial infiltrations in both lungs within the 48 hours after admission.

active bleeding over the whole right upper and lower lung, which confirmed acute pulmonary hemorrhage. The abnormal junctional escaped rhythm was noted on electrocardiography. The echocardiography demonstrated globally severe hypokinesis of right ventricular (RV) and left ventricular (LV) with severe impairment of LV & RV systolic function. Acute myocarditis was suspected. Dobutamine was prescribed.

According to the contact history of rats' infestations and clinical presentation of the patient including pharyngeal erythema, abdominal cramping pain, acute pulmonary hemorrhage, leptospirosis was suspected. Serology for microscopic agglutination test (MAT) was done (on hospital day 2). Penicillin 3 million units intravenously every 6 hours and ciprofloxacin 200mg intravenously every 12 hours were prescribed. The anti-neutrophil cytoplasmic antibody (ANCA), rheumatoid factor, anti-glomerular basement membrane (GBM) antibodies, anti-nuclear antibody (ANA), Anti-DNA anti-body, the Venereal Disease Research Laboratory (VDRL) /Rapid Plasma Reagin (PRP) test and anti-Human Immunodeficiency Virus (anti-HIV) antibody were all negative.

Leptospirosis was confirmed by MAT (*Leptospira shermani*: 1:3200, *Leptospira canicola*: 1:1600). The culture result was negative. The patient stayed in the hospital for a duration of one month due to multi-organ damage (pulmonary hemorrhage, myocarditis, acute kidney injury, jaundice and respiratory failure) and nosocomial infection (extended-spectrum β -lactamases producing *Klebsiella pneumoniae* bacteremia, *Pseudomonas aeruginosa* pneumonia). After intensive treatment including blood transfusion and antibiotic therapy, his heart, lung, and renal functions improved. He was liberated from mechanical ventilation and recovered uneventfully. There were no permanent sequelae at a four-month follow-up.

Discussion

The patient became infected at a poorly hygienic place with rodent infestation. He presented diverse symptoms from fever, myalgia, and epigastric tenderness to multi-organ dysfunction including pulmonary hemorrhage, myocarditis, acute kidney injury, jaundice and respiratory failure. This is compatible with a case-control study with 22 confirmed diagnoses of leptospirosis out of 169 suspected cases in Taiwan demonstrating fever (95.6%), acute renal failure (86.4%), myalgia (72.2%) and jaundice (63.6%) as the most common presentations of leptospirosis².

Pulmonary involvement in leptospirosis ranges from 20-70% of patients³. Pulmonary symptoms occur in both anicteric and icteric forms of leptospirosis. Pulmonary hemorrhage is the most serious pulmonary manifestation. Respiratory symptoms usually appear between the fourth and sixth day of disease and may lead to death in less than 72 hours. Mortality rates can be as high as 30-60%³.

Concerning the pathogenesis of lung injury in leptospirosis, two main mechanisms are suggested: a toxin-mediated mechanism and/or exacerbated immune responses of the host⁴. A toxin-mediated capillary vasculitis is believed to cause lung hemorrhage⁵. On chest radiograph, a case-control study of 118 patients with leptospirosis in Thailand⁶ demonstrated the most common finding was bilateral diffuse air-space disease, characterized by multiple, ill-defined nodules in both lungs, some of which subsequently became confluent and turned into patchy infiltration. The patients who had an abnormal chest radiograph were more severely ill and needed longer hospitalization than the others⁶.

Tubular dysfunction and pathogen-induced tubule-interstitial nephritis is the principle renal lesion to cause renal failure. *Leptospira* outer membrane proteins (OMPs) may elicit tubular injury and inflammation⁷. Renal function returns typically

to normal after early treatment. A case-control-study of Leptospirosis in Taiwan showed prominent presentations with increased incidence of bilateral enlarged kidneys, sterile pyuria, and hypokalemia as compared with excluded cases⁸.

Renal disease associated with pulmonary hemorrhage is seen in a variety of clinical disorders⁹. Common pulmonary-renal syndromes including anti-GBM disease and ANCA – associated vasculitis. The infection is the differential diagnosis as well.

A case report mentioned about one misdiagnosed leptospirosis patient presenting with pulmonary-renal syndrome on admission⁹. Anti-GBM disease, anti-ANCA-related vasculitis and leptospirosis have the similar constitutional symptoms such as fever, arthralgias, myalgias and flu-like syndrome. Nally and associates demonstrated the deposition of immunoglobulin G (IgG), IgA and C3 along the alveolar basement membrane of infected guinea pigs in a leptospirosis animal model, which may be similar to the pattern that seen in Goodpasture's syndrome¹⁰.

Andrade and colleagues¹¹ investigated the expression of water and sodium transporters in the kidneys and lungs of leptospirosis cases. They observed altered renal expression of the Na-K-2Cl cotransporter NKCC2 and upregulation of the Na-K-2Cl cotransporter NKCC1 in the lungs. These findings may explain the pathogenesis of both renal and pulmonary failure in severe forms of leptospirosis.

A detailed exposure history taken from the suspected patients is critical for diagnosis. Biochemical, hematologic and urinalysis parameters in leptospirosis are variable and non-specific. Classic Weil's disease may demonstrate elevated blood urea nitrogen, serum creatinine, bilirubin, GOT, and GPT. In hematologic abnormalities, thrombocytopenia appears independently of disseminated intravascular coagulation and may be concurrent with severe endotoxin injury of leptospirosis³. Thrombocytopenia develops up-to 50% of patients and

usually correlates with nonoliguric renal failure as a possible early hint of leptospirosis¹².

The MAT is the gold standard for serologic diagnosis of leptospirosis. The criterion for a positive MAT is a four-fold increase in antibody titer or a conversion from seronegative to a titer of $\geq 1:100$. Owing to the high inter-laboratory variation in MAT, the commercially available assays that can detect IgM antibodies during the first week of illness are on the rise¹³.

Current antimicrobial treatments for leptospirosis include doxycycline, penicillin, and the third-generation cephalosporin. All regimens were observed to be therapeutically equivalent in one randomized trial¹⁴. For moderate/severe leptospirosis, penicillin (1.5 million units IV Q6h) or ceftriaxone (1g IV Qd) or cefotaxime (1g IV Q6h) should be used. Before the diagnosis can be confirmed, broad-spectrum parenteral antibiotic is required for suspicion manifesting as multiorgan system dysfunction¹. Mild disease should be treated with oral antibiotics, in particular doxycycline (100mg po bid)¹. It is also reported as an effective prophylaxis for soldiers training in endemic areas¹⁵.

Conclusion

It is a challenge to diagnose the infection of *Leptospira* because of the diverse presentations. The most common triad is fever, jaundice, and acute renal failure. In addition to hepatic and renal dysfunction, leptospirosis should be seriously considered in patients with pulmonary symptoms. Early awareness of the distinct presentations of leptospirosis and prompt antibiotic therapy can dramatically save the patients.

Acknowledgement

We would like to thank the Taiwan Centers for Disease Control for providing laboratory data for our manuscript.

References

1. Speelman P, Harkskeerl R. Leptospirosis. In: Fauci AS, Braunwald E, Kasper DL, et al. eds. Harrison's principles of internal medicine. 18th ed. New York: McGraw-Hill. 2012; 1392-96.
2. Yang HY, Hsu PY, Pan MJ, et al. Clinical distinction and evaluation of leptospirosis in Taiwan – a case-control study. *J Nephrol* 2005; 18: 45-53.
3. Dolhnikoff M, Mauad T, Bethlem EP, Carvalho CR. Leptospiral pneumonias. *Curr Opin Pulm Med* 2007; 13: 230-5.
4. Bharti AR, Nally JE, Ricardi JN, et al. Leptospirosis: a zoonotic disease of global importance. *Lancet Infect Dis* 2003; 3: 757-71.
5. Luks AM, Lakshminarayanan S, Hirschmann JV. Leptospirosis presenting as diffuse alveolar hemorrhage: case report and literature review. *Chest* 2003; 123:639-43.
6. Edwards CN, Nicholson GD, Everard CO. Thrombocytopenia in leptospirosis. *Am J Trop Med Hyg* 1982; 31:827-9.
7. Yang, CW. Leptospirosis renal disease: understanding the initiation by Toll-like receptors. *Kidney International* 2007; 72: 918-25.
8. Rodriguez W, Hanania N, Guy E, Guntupalli J. Pulmonary-renal syndromes in the intensive care unit. *Crit Care Clin* 2002; 18: 881-95.
9. Kishimoto M, Brown JD, Chung HH, Howman S. Leptospirosis misdiagnosed as pulmonary-renal syndrome. *Am J Med Sci* 2004; 328:116-20.
10. Nally JE, Chantranuwat C, Wu XY, et al. Alveolar septal deposition of immunoglobulin and complement parallels pulmonary hemorrhage in a guinea pig model of severe pulmonary leptospirosis. *Am J Pathol* 2004; 164:1115-27.
11. Andrade L, Rodrigues AC Jr, Sanches TR, Souza RB, Seguro AC. Leptospirosis leads to dysregulation of sodium transporters in the kidney and lung. *Am J Physiol Renal Physiol* 2007; 292: F586-92.
12. Yang HL, Jiang XC, Zhang XY, et al. Thrombocytopenia in the experimental leptospirosis of guinea pig is not related to disseminated intravascular coagulation. *BMC Infect Dis* 2006; 6:19.
13. Bajani MD, Ashford DA, Bragg SL, et al. Evaluation of four commercially available rapid serologic tests for diagnosis of leptospirosis. *J Clin Microbiol* 2003; 41:803-9.
14. Suputtamongkol Y, Niwattayakul K, Suttinont C, et al. An open, randomized, controlled trial of penicillin, doxycycline, and cefotaxime for patients with severe leptospirosis. *Clin Infect Dis* 2004; 39:1417-24.
15. Brett-Major DM, Coldren R. Antibiotics for leptospirosis. *Cochrane Database Syst Rev* 2012; 15: 2: CD008264.

猛暴性鉤端螺旋體感染：病例報告及文獻回顧

蘇冠仁¹ 葉彥成^{1,2} 班仁知^{1,2}

國軍高雄總醫院 內科部¹ 感染科²

摘要

鉤端螺旋體是一種人畜共通感染疾病，大多因人體接觸到老鼠尿液而感染。在台灣偶發性感染大多盛行於洪水或颱風發生後。一位鉤端螺旋體感染病患，其工作環境衛生極差，到院時看似流感症狀，卻在兩天內進展成肺出血及急性腎衰竭等重症，即時地投予盤尼西林大多有不錯的預後。