

Tension Chylothorax as A Complication from Percutaneous Catheterization: A Case Report

Zih-Jie Yan¹, and Ping-Fang Chiu²

¹Department of Internal Medicine, ²Division of Nephrology,
Changhua Christian Hospital, Changhua County, Taiwan

Abstract

Chylothorax is a rare complication of central venous catheterization. Massive chylothorax could result in respiratory failure and unstable hemodynamic status, causing high mortality. The classic appearance of chyle is milky white, but it could also show other appearances. Central venous catheterization is a common procedure in intensive care units and in patients with end-stage renal disease for undergoing hemodialysis. We report a case of a new diagnosis of microscopic polyangiitis complicated with rapidly progressive glomerulonephritis. Tension chylothorax developed after the placement of permanent catheter. After pigtail drainage of pleural effusion and supportive care, patient was stabilized. Her chylothorax had completely resolved. (J Intern Med Taiwan 2018; 29: 323-326)

Key Words: Tension hydrothorax, Chylothorax, Central vein catheterization

Introduction

Chylothorax refers to leakage of chyle from the lymphatic system, which accumulates in the pleural space.¹ The cause of chylothorax could be traumatic and nontraumatic. Traumatic causes could be surgical and nonsurgical.² Chylothorax is a rare complication of central venous catheter placement, and only few cases have been reported.³ Permanent catheter implantation is common in patients with end-stage renal disease. We report a case of tension chylothorax after the implantation of permanent catheter.

Case presentation

A 58-year-old woman with a history of chronic hepatitis B and hypertension has been followed up

at the clinic for years. There was rapid deterioration of renal function within 1 month. Pauci-immune crescentic glomerulonephritis was confirmed from kidney biopsy. The patient was diagnosed with microscopic polyangiitis complicated with rapidly progressive glomerulonephritis. Laboratory analysis showed as follows: WBC count $4.7 \times 10^3/\mu\text{L}$, RBC count $3.60 \times 10^6/\mu\text{L}$, Hb 9.8 g/dL, MCV 80.5 fL, platelet count $201 \times 10^3/\mu\text{L}$, creatinine 9.86 mg/dL, Na 135 mmol/L, K 6.9 mmol/L, uric acid 9.6 mg/dL, Ca 7.8 mg/dL, P 8.0 mg/dL, antityeloperoxidase Ab 60.0 IU/mL, and antiprotease 3 Ab <0.2 IU/mL. Urine sediments showed the following results: RBC >100/HPF, RBC >550/ μL , WBC 7.5/HPF, WBC 41/ μL , granular casts 4/LPF, and absence of bacteria. She received double filtration

plasmapheresis (DFPP), pulse steroid therapy, and cyclophosphamide. Due to poor response despite the above treatment, a second course of plasmapheresis (DFPP), pulse steroid therapy, and cyclophosphamide was prescribed. She developed persistent oliguria and azotemia, after which permanent catheter implantation was arranged.

On the next day after catheter implantation, she developed progressive respiratory distress and had massive ecchymosis around the insertion site of the permanent catheter. Hypotension was noted at the beginning of the hemodialysis session. A chest radiograph showed massive right pleural effusion (Figure 1). Laboratory analysis revealed the following results: Hb 8.7 g/dL, WBC $9.0 \times 10^3/\mu\text{L}$, platelet $16 \times 10^3/\mu\text{L}$, PT 20.5 s, APTT >240 s, and triglyceride 126 mg/dL. Pleural tapping on the right side was arranged that yielded 500 ml of a pink and cloudy pleural fluid (Figure 2). Pleural effusion analysis revealed the following results: RBC count 20,300/ μL , nucleated cell count 49/ μL , leukocyte count 47/ μL , neutrophil 0%, lymphocyte 6%, monocyte 85%, pH 7.4, triglyceride 283 mg/dL, protein <1.0 g/dL, LDH 109 U/L, and cholesterol 13 mg/dL. Gram staining of pleural fluid was negative. Tension chylothorax was suspected. A pigtail catheter was inserted into the right pleural space. Computed

tomography of the chest confirmed the permanent catheter to be in the proper position (Figure 3). The drain amounts were as follows: 500 ml on the 1st day, 890 ml on the 2nd day, 130 ml on the 3rd day, and <100 ml on the next 3 days. The pigtail draining tube was removed on the 6th day. A low-fat diet was suggested. Her dyspnea showed improvement. A follow-up chest X-ray revealed clearance in the right lung field, and a follow-up pleural fluid analysis showed a triglyceride level of 27 mg/dL.

Discussion

Chylothorax is caused by the damage of thoracic duct damage or its tributaries, resulting in chyle leakage from the lymphatic system into the pleural space. The clinical manifestations include dyspnea, chest pain, and cough and may occur as those due to any pleural effusion.⁴ The most common cause of chylothorax is surgery or trauma (50% of cases).² Implantation of permanent catheter is frequent in uremic patient carrying unexpected course. Chylothorax is a seldom complication during the operation.

The typical appearance of chylothorax is milky. However, according to a report about 61 patients, the gross appearance of the pleural fluid can be described as milky (44%), serous (26%), serosanguinous (26%), or bloody (3%).⁵ In our case,

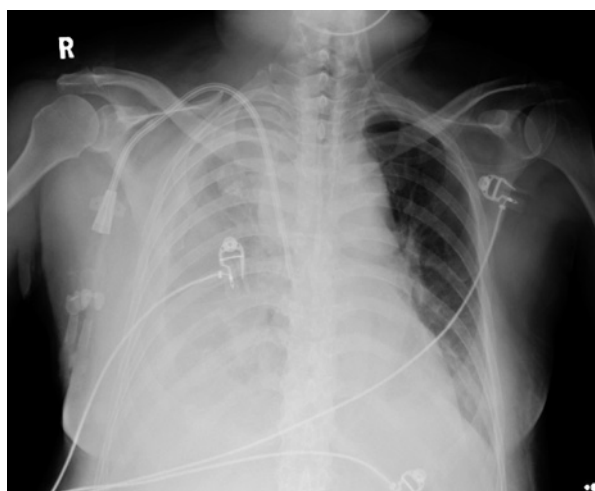


Figure 1. Chest radiograph at the time of dyspnea showing massive right pleural effusion.



Figure 2. Pleural tapping revealed fluid with a pink and cloudy appearance.

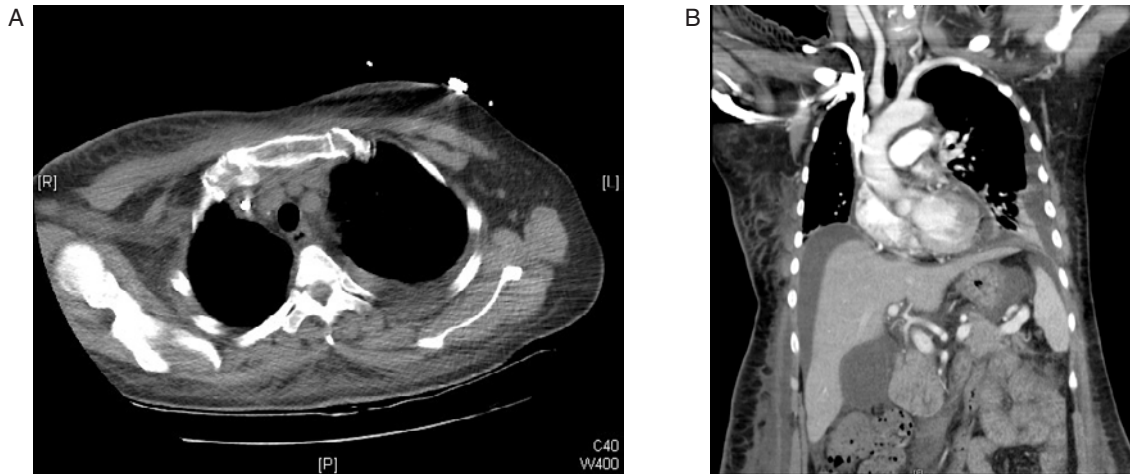


Figure 3. Computed tomography of the chest (A, B), which showed the permanent catheter in the superior vena cava, right pleural effusion.

the pink and cloudy appearance raised the suspicion of empyema or chylothorax. However, pleural fluid analysis revealed transudate, and a definite culture showed no bacterial growth. According to the diagnostic criteria for chylothorax, the triglyceride concentration must be >110 mg/dL and the cholesterol level must be <200 mg/dl. Our case was compatible with the diagnosis of chylothorax.

Both conservative and operative treatments have been described for traumatic chylothorax. Conservative management includes pleural cavity drainage, reduction of chyle flow through a low-fat diet, nutritional support, and maintenance of fluid and electrolyte balance.⁶ Pleural drainage could relieve dyspnea caused by the pleural fluid. The rate of resolution with initial treatment measures has been reported to be 50% in traumatic causes.⁷ Surgery is recommended in patients when the chyle leak exceeds 1.5 L/day, the output is >1 L/day for 5 or more days, and the drainage is longer than 14 days.⁶

Tension hydrothorax is defined as a large pleural effusion that increases intrathoracic pressures enough to shift the mediastinal structures and impede venous return. Once tension has begun, the symptoms include tachycardia, resting dyspnea, and jugular venous distention.⁸ If left untreated, tension

hydrothorax can result in respiratory failure, hemodynamic compromise, and cardiopulmonary collapse.⁹ Chylothorax is a rare complication of this procedure, and only five such cases have been reported in the literature.³ Tension chylothorax has been reported in patients after pneumonectomy.^{10,11} However, to our knowledge, tension chylothorax caused by central venous catheterization has never been reported. In our case, computed tomography

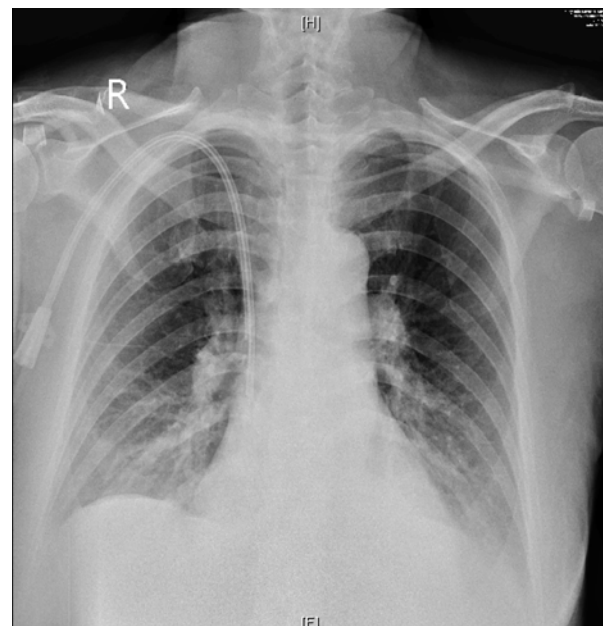


Figure 4. Followed chest radiograph 8 days post pigtail insertion showed improved right pleural effusion.

of the chest confirmed that the catheter was in the proper position. In addition, since the patient showed clinical improvement after our treatment, we did not remove the permanent catheter. Traumatic puncture of the lymph drainage system during catheterization was suspected to be the cause of chylothorax in our patient.

In conclusion, we first reported a rare case of traumatic tension chylothorax complication after permanent catheter implantation. We should consider this rare complication in a patient who has ever received a central venous procedure and has a massive amount of pleural effusion with a cloudy appearance. Screening of pleural triglyceride levels would be helpful for an early diagnosis.

References

1. Macfarlane JR, Holman CW. Chylothorax. *Am Rev Respir Dis* 1972; 105: 287e91.
2. Doerr CH, Allen MS, Nichols FC 3rd, Ryu JH. Etiology of chylothorax in 203 patients. *Mayo Clin Proc* 2005; 80: 867.
3. Saxena P, Shankar S, Kumar V, Naithani N. Bilateral chylothorax as a complication of internal jugular vein cannulation. *Lung India* 2015; 32: 370-4.
4. McGrath EE, Blades Z, Anderson PB. Chylothorax: Aetiology, diagnosis and therapeutic options. *Respir Med* 2010; 104: 1e8.
5. Maldonado F, Hawkins FJ, Daniels CE, Doerr CH, Decker PA, Ryu JH. Pleural Fluid Characteristics of Chylothorax. *Mayo Clin Proc* 2009; 84: 129-33.
6. Pillay TG, Singh B. A review of traumatic chylothorax. *Injury* 2016; 47: 545-50.
7. Maldonado F, Cartin-Ceba R, Hawkins FJ, Ryu JH. Medical and surgical management of chylothorax and associated outcomes. *Am J Med Sci* 2010; 339: 314-8.
8. Demidovich J, Nasser H, Vasoya AP, Morley TF. Tension hydrothorax: a case report. *Clin Pulm Med* 2012; 19: 50-2.
9. Maroun R, Chalhoub M, Harris K. Right internal jugular venous cannulation complicated by tension hydrothorax. *Heart Lung* 2013; 42: 372-4.
10. Yadav H, Nolan ME, Nichols FC, Daniels CE. Tension chylothorax following pneumonectomy. *Respiratory Medicine Case Reports* 2015; 14: 16e18.
11. Ammori JB, Pickens A, Chang AC, Orringer MB. Tension Chylothorax. *Ann Thorac Surg* 2006; 82: 729-30.

中心靜脈導管置放後續發的張力性乳糜胸：病例報告

顏子傑¹ 邱炳芳²

彰化基督教醫院 ¹內科部 ²腎臟科

摘要

乳糜胸是中心靜脈導管置放術的罕見併發症。大量乳糜胸可能導致呼吸衰竭和不穩定的血液動力學狀態，導致高死亡率。典型乳糜的外觀是乳白色，但它也可以是其他外觀。中心靜脈導管置放術是重症監護病房和末期腎病患者進行血液透析的常見手術。我們報告一例新診斷顯微性多血管炎(Microscopic polyangiitis)合併快速進行性腎炎(Rapid Progressive Glomerulonephritis)的病例，在永久性導管置入後，發生張力性乳糜胸。在豬尾巴導管引流胸腔積液和支持治療後，患者得到穩定，乳糜胸獲得改善。